# RUSH exam

## Undifferentiated Hypotension Meet Emergency Ultrasound!

Cory Wittrock, MD

## *No Relevant Financial Conflicts:*

Relevant to the content of this educational activity, I do not have any financial conflicts with commercial interest companies to disclose.

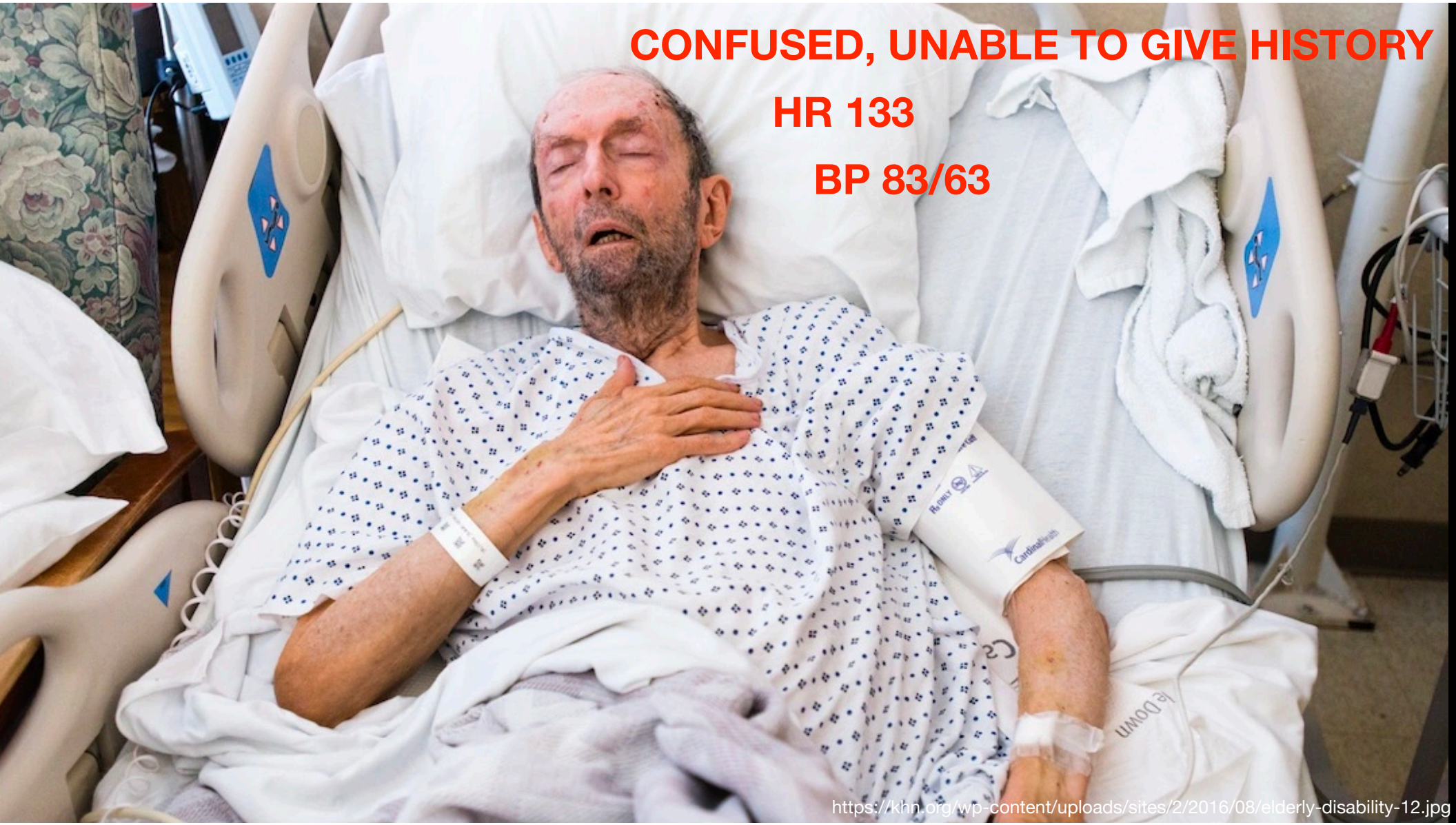
CONFUSED, UNABLE TO GIVE HISTORY
HR 133
BP 83/63
https://khn.org/wp-content/uploads/sites/2/2016/08/elderly-disability-12.jpg

# RUSH exam components

Pump:

HEART

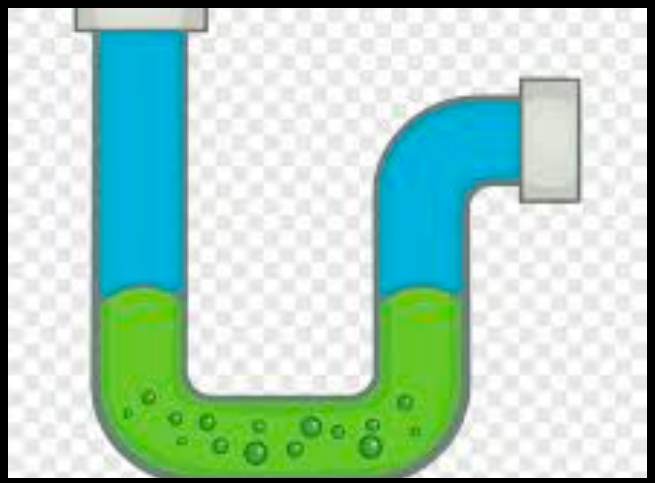

Pipes:

IVC

AORTA

DVT

Tank:

PERITONEAL CAVITY

THORACIC CAVITY

# HI-MAP

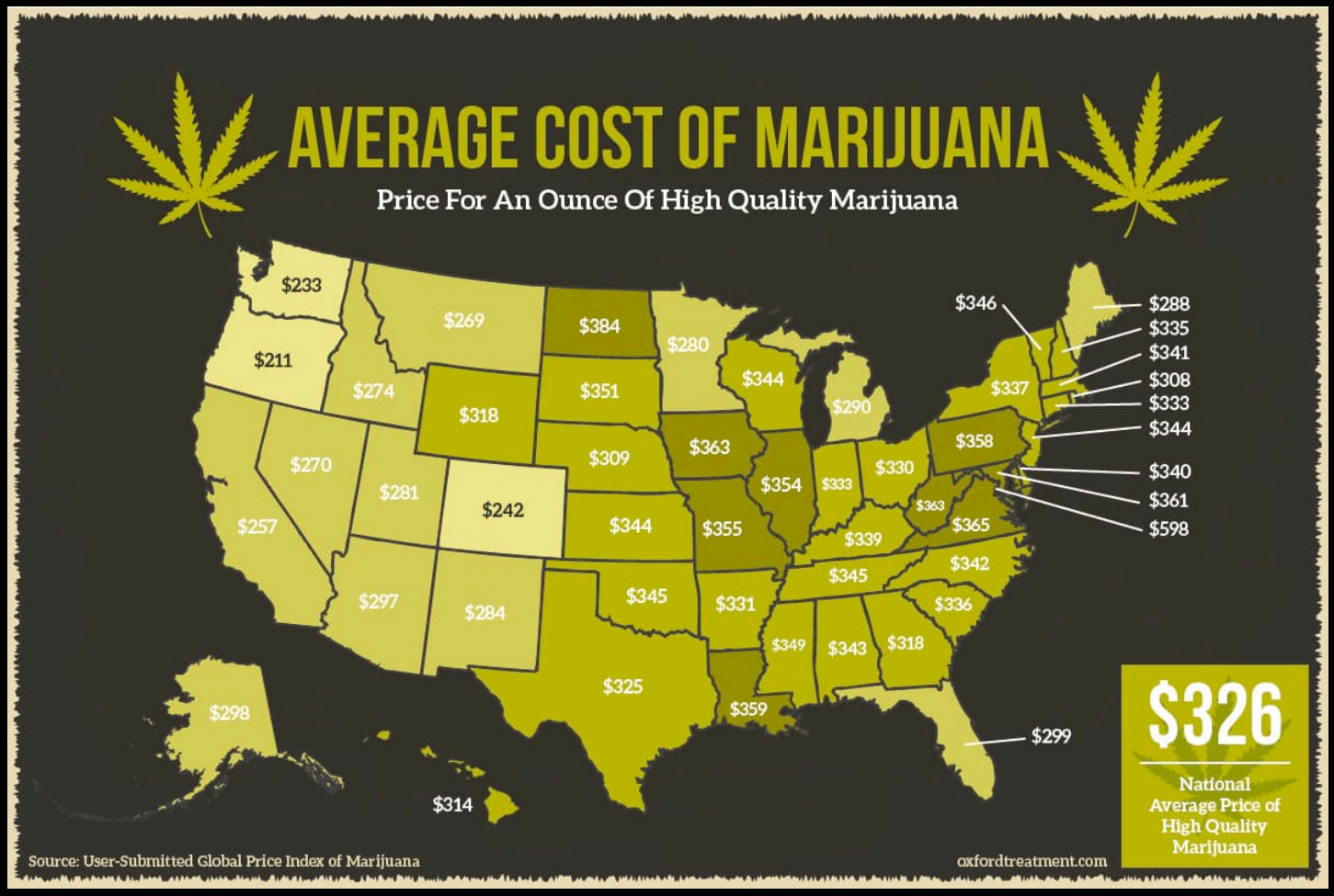
AVERAGE COST OF MARIJUANA
Price For An Ounce Of High Quality Marijuana
$233
$211
$269
$274
$384
$318
$351
$280
$344
$290
$337
$346
$288
$335
$341
$308
$333
$344
$358
$363
$309
$270
$281
$242
$257
$344
$354
$333
$330
$363
$340
$361
$598
$355
$339
$365
$342
$345
$297
$284
$345
$331
$336
$349
$343
$318
$325
$359
$299
$298
$314
$326
National Average Price of High Quality Marijuana
Source: User-Submitted Global Price Index of Marijuana
oxfordtreatment.com

# HI-MAP

- **H** HEART
- **I** IVC
- **M** MORRISON'S POUCH (FAST)
- **A** AORTA
- **P** PULMONARY

# Differential Dx:

- Cardiogenic Shock
- Obstructive Shock
  - Tamponade
  - PE
  - Tension PTX
- Hypovolemic Shock
  - Peritoneal Bleeding
  - Hemothorax
  - AAA rupture
  - Aortic Dissection
- Distributive Shock
  - Sepsis

# H HEART

- Probe Position A:
  Parasternal Views
  Long / Short Axis
- Probe Position B:
  Subxiphoid View
- Probe Position C:
  Apical View

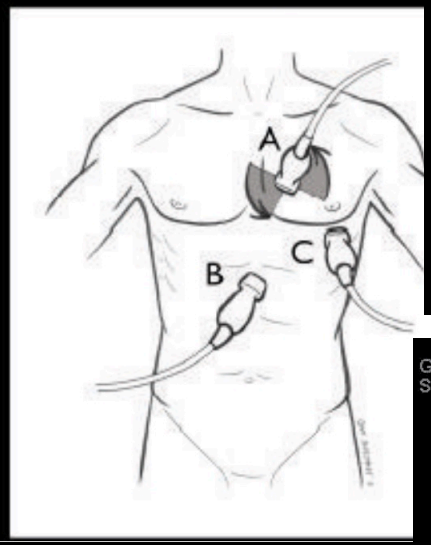

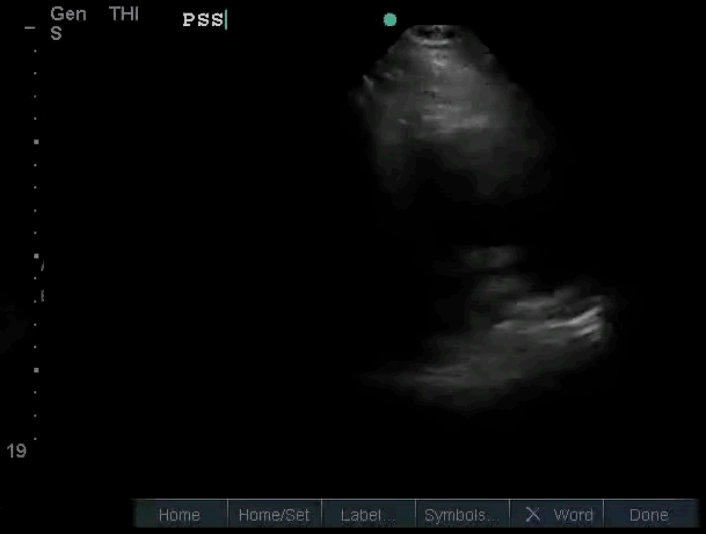

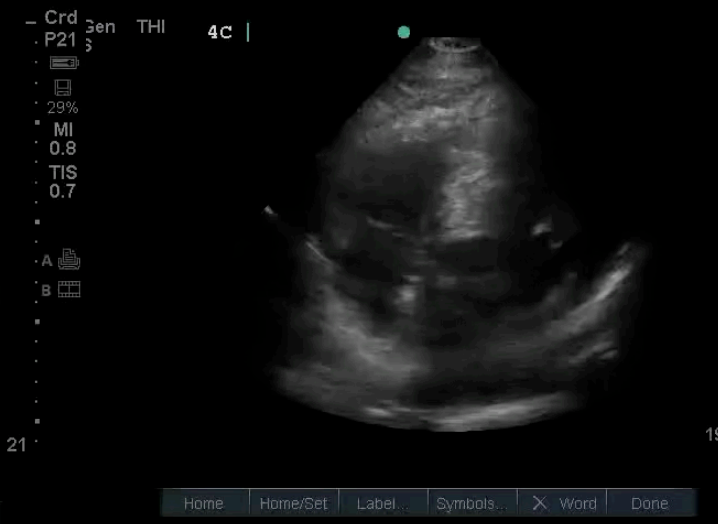

# H HEART

## Pericardial Effusion?

## Left Ventricular Contractility?

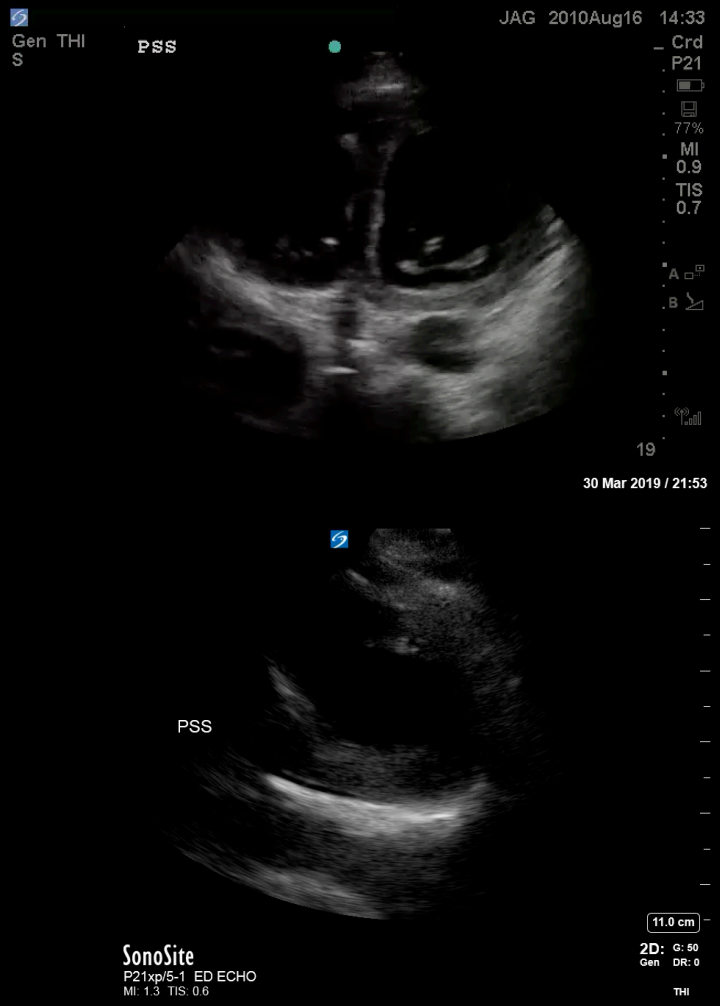


## Right Ventricular Strain?

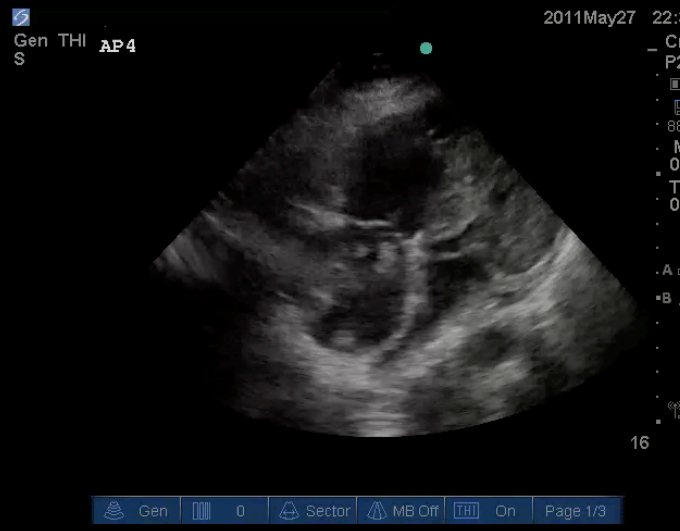

# IVC

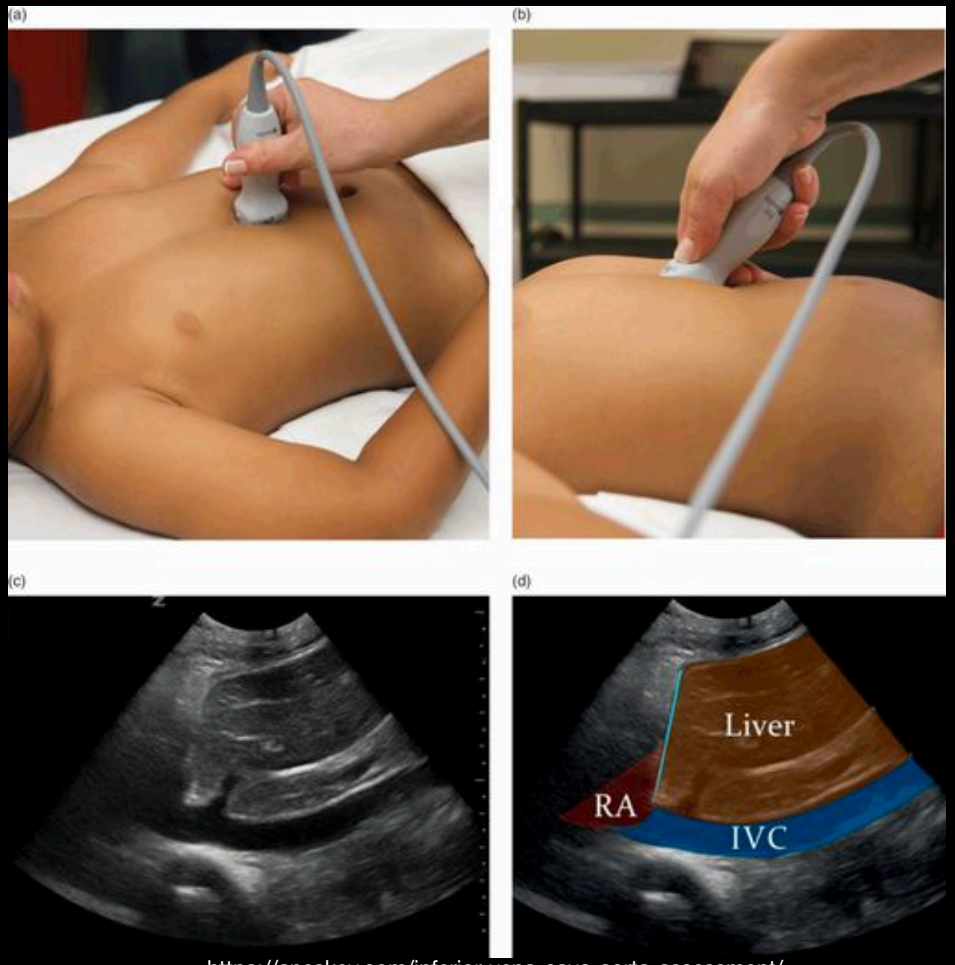


ED

https://aneskey.com/inferior-vena-cava-aorta-assessment/

# IVC

## Full?

## Collapsed ?

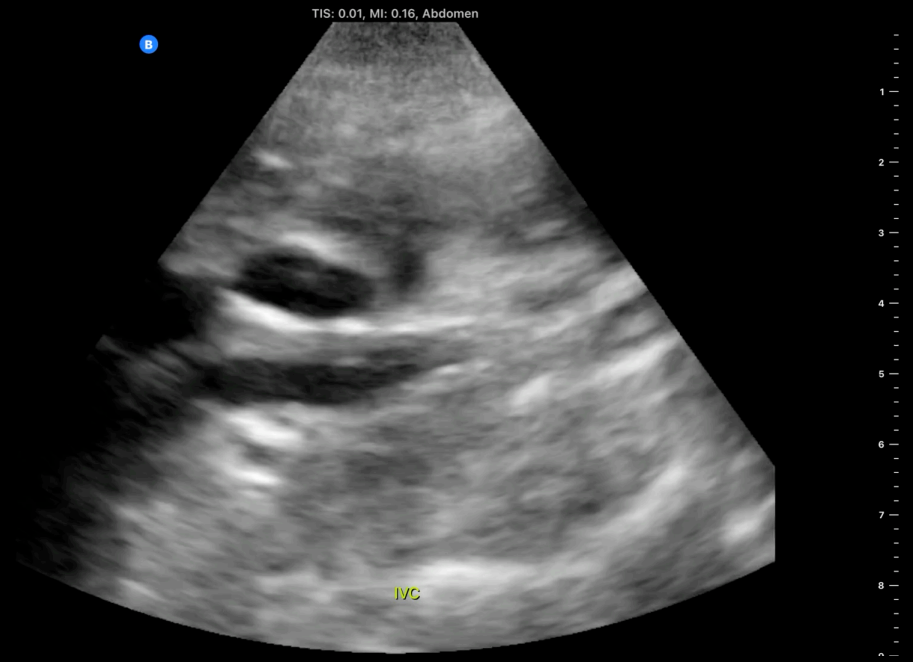

# M MORRISON'S POUCH (FAST)

- RUQ-hepatorenal
- LUQ-splenorenal
- Suprapubic-bladder

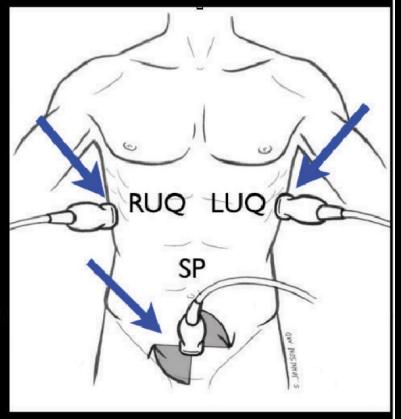


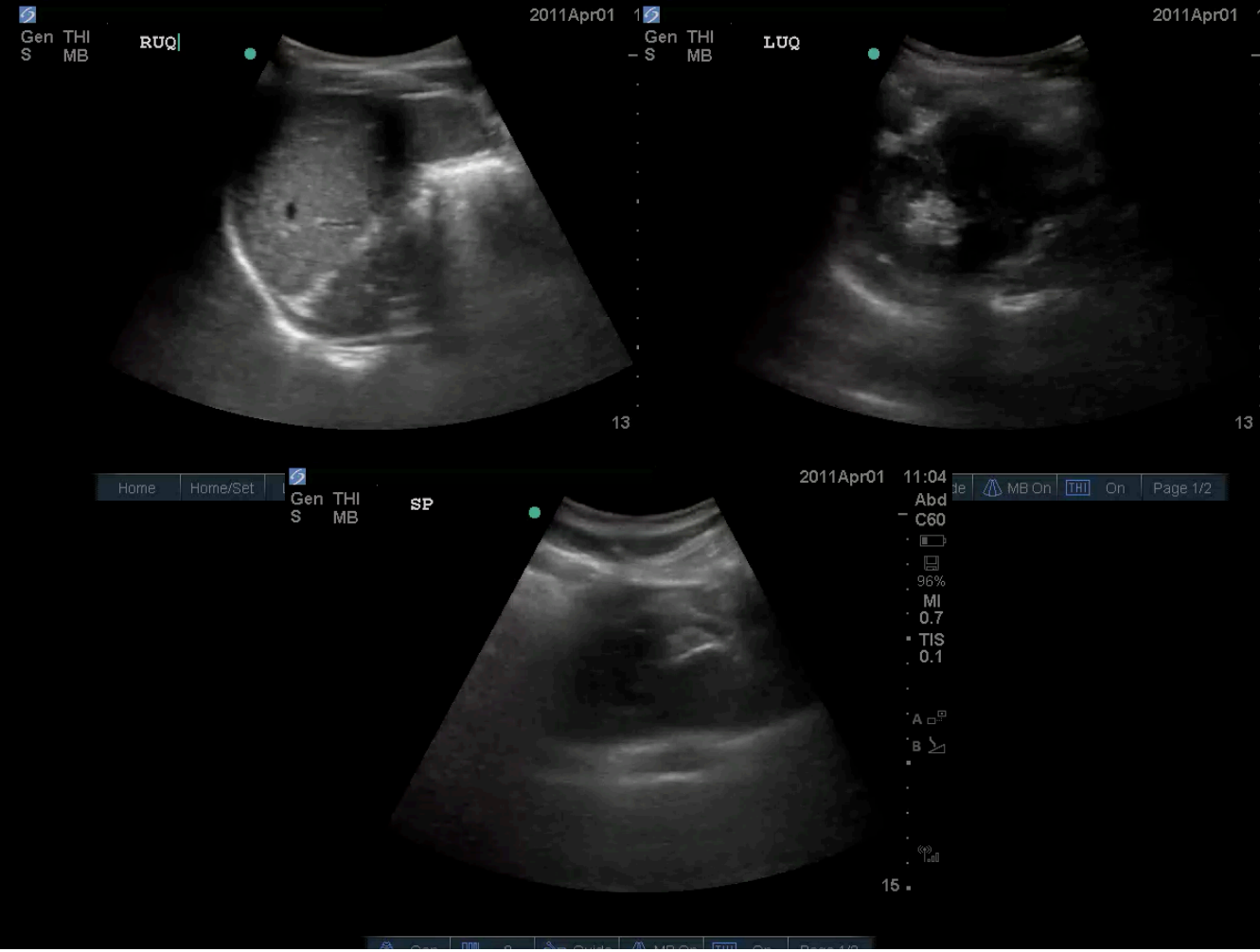

# M MORRISON'S POUCH (FAST)

## Free Fluid in the Abdomen?

# A AORTA

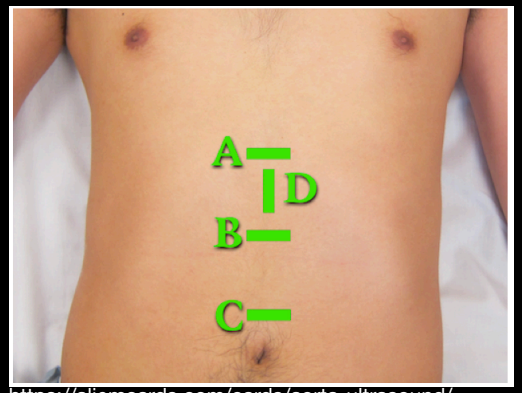


https://aliemcards.com/cards/aorta-ultrasound/

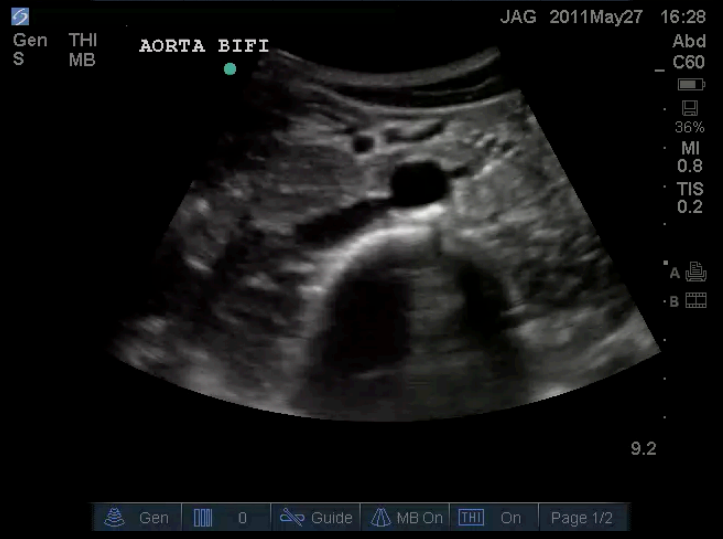

# A AORTA

## Abdominal Aortic Aneurysm? (>3cm)

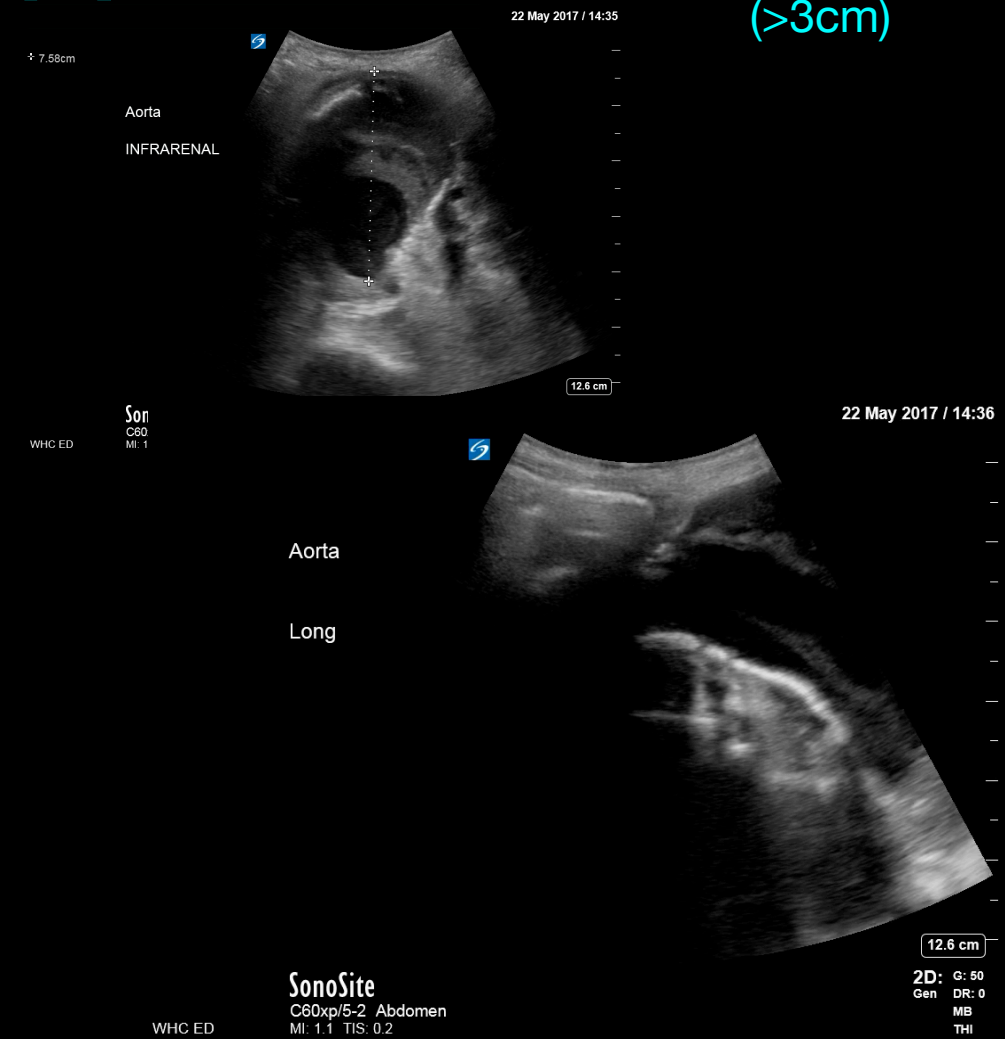


## Dissection Flap?

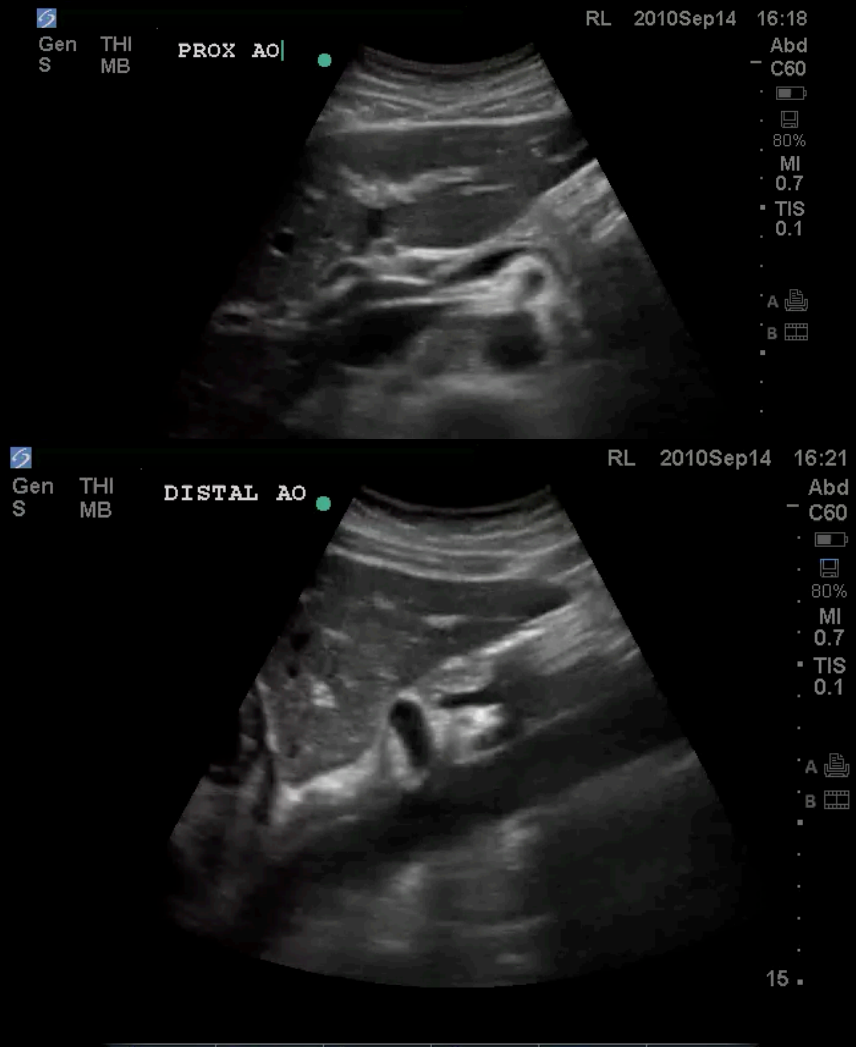

# P PULMONARY

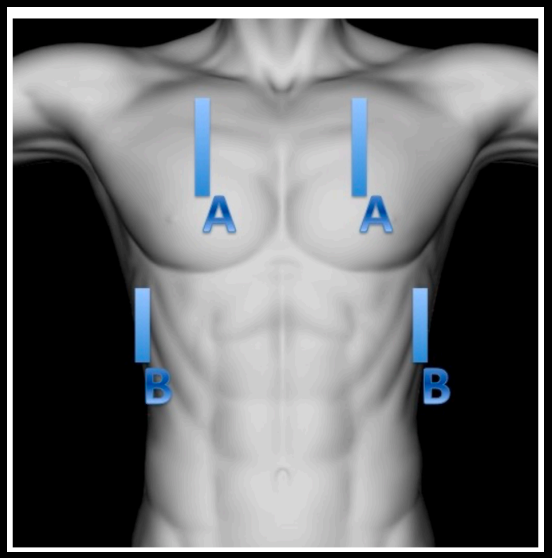


https://sjrhem.ca/pocus-pleural-effusion/

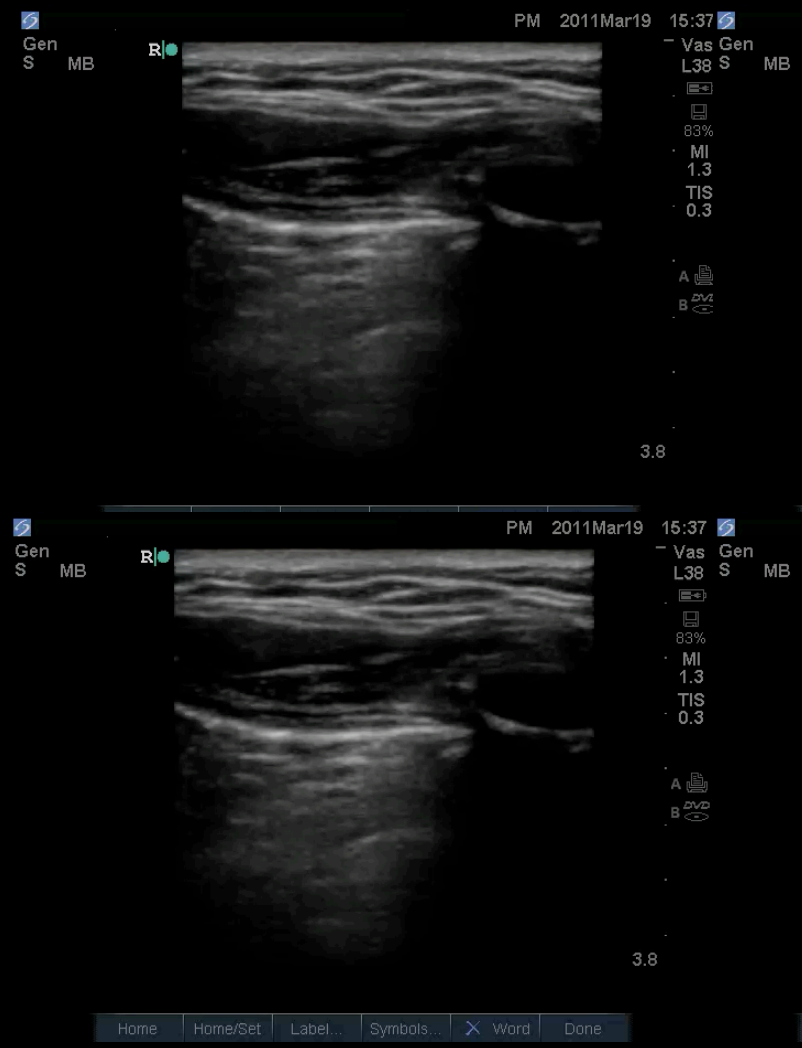


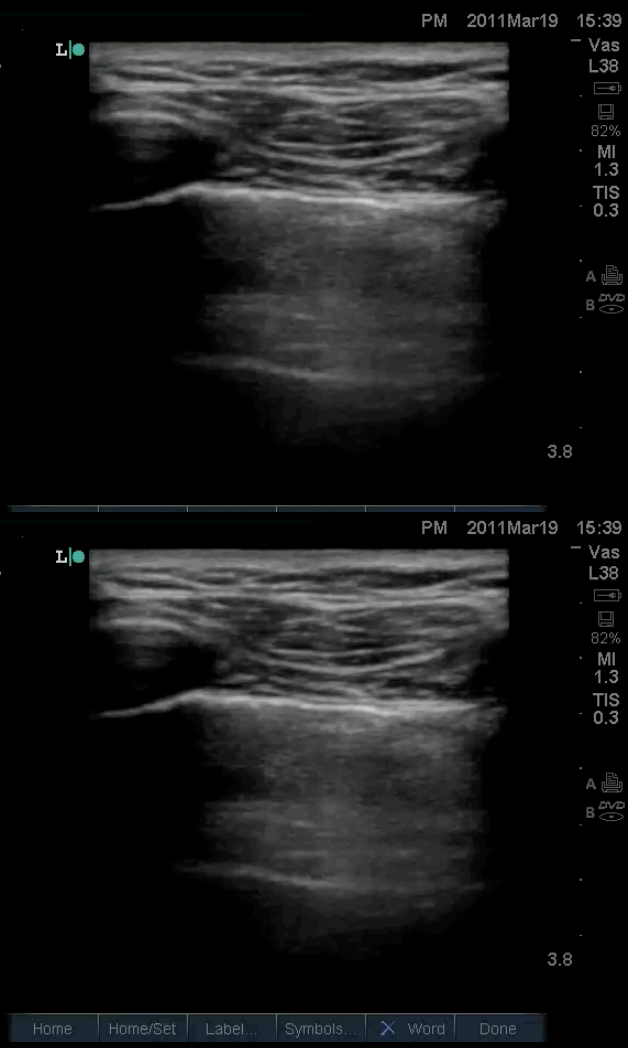

# P PULMONARY

## Pleural Fluid?

## Pulmonary Edema?

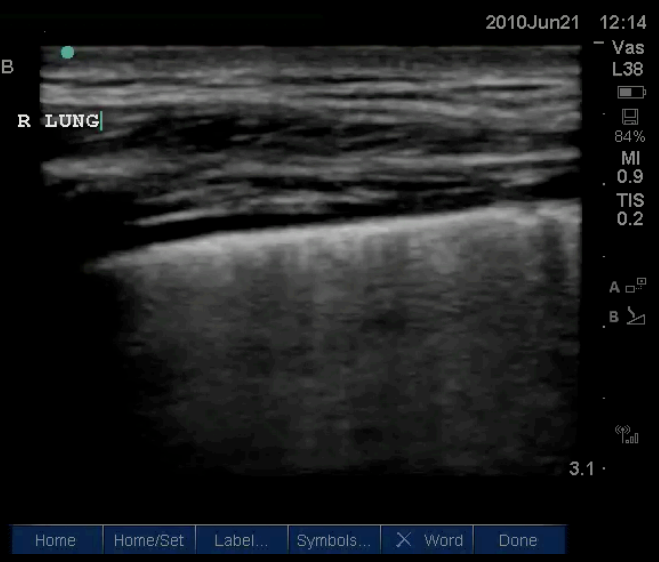


## Tension Pneumothorax

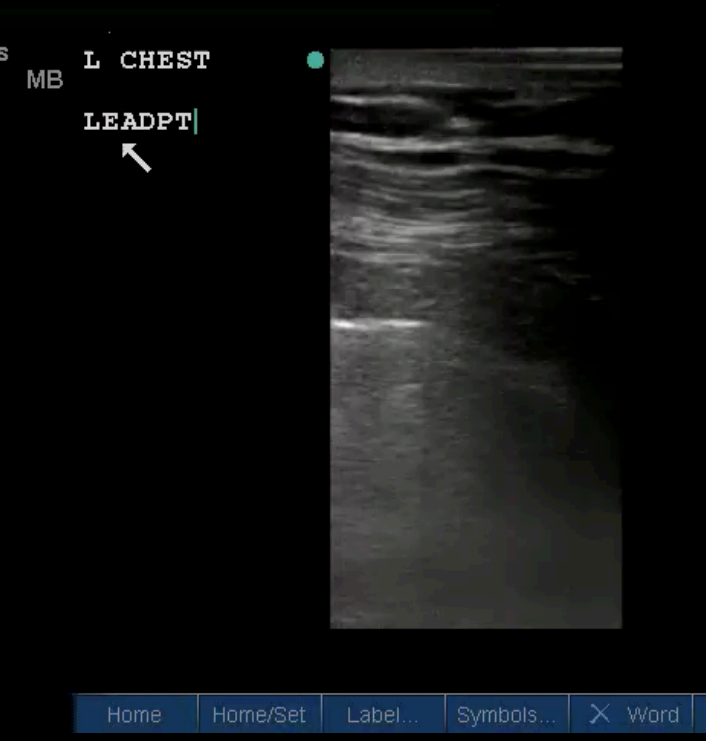

# HI-MAP

- **H** HEART
- **I** IVC
- **M** MORRISON'S POUCH (FAST)
- **A** AORTA
- **P** PULMONARY

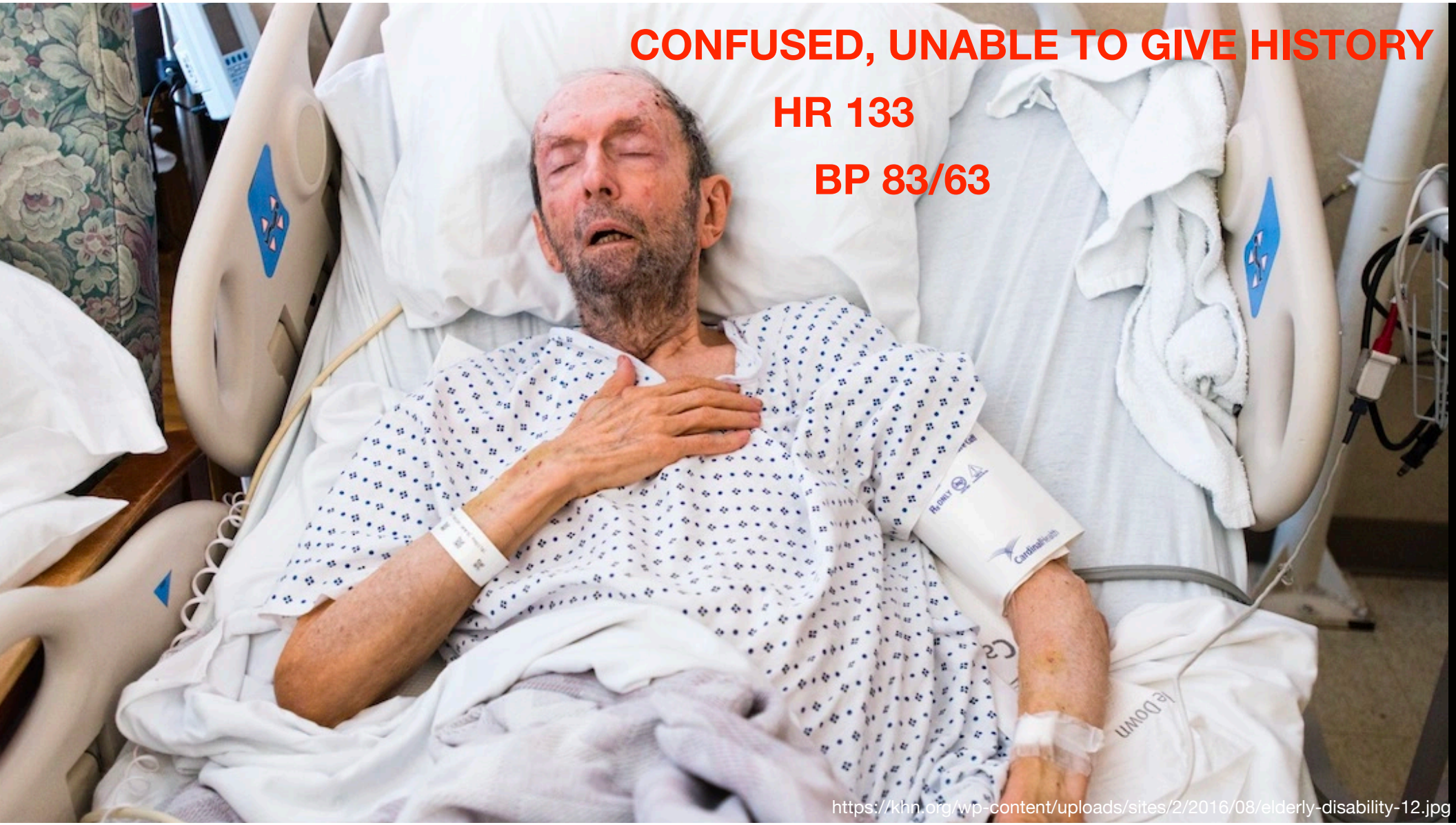
CONFUSED, UNABLE TO GIVE HISTORY
HR 133
BP 83/63
https://khn.org/wp-content/uploads/sites/2/2016/08/elderly-disability-12.jpg

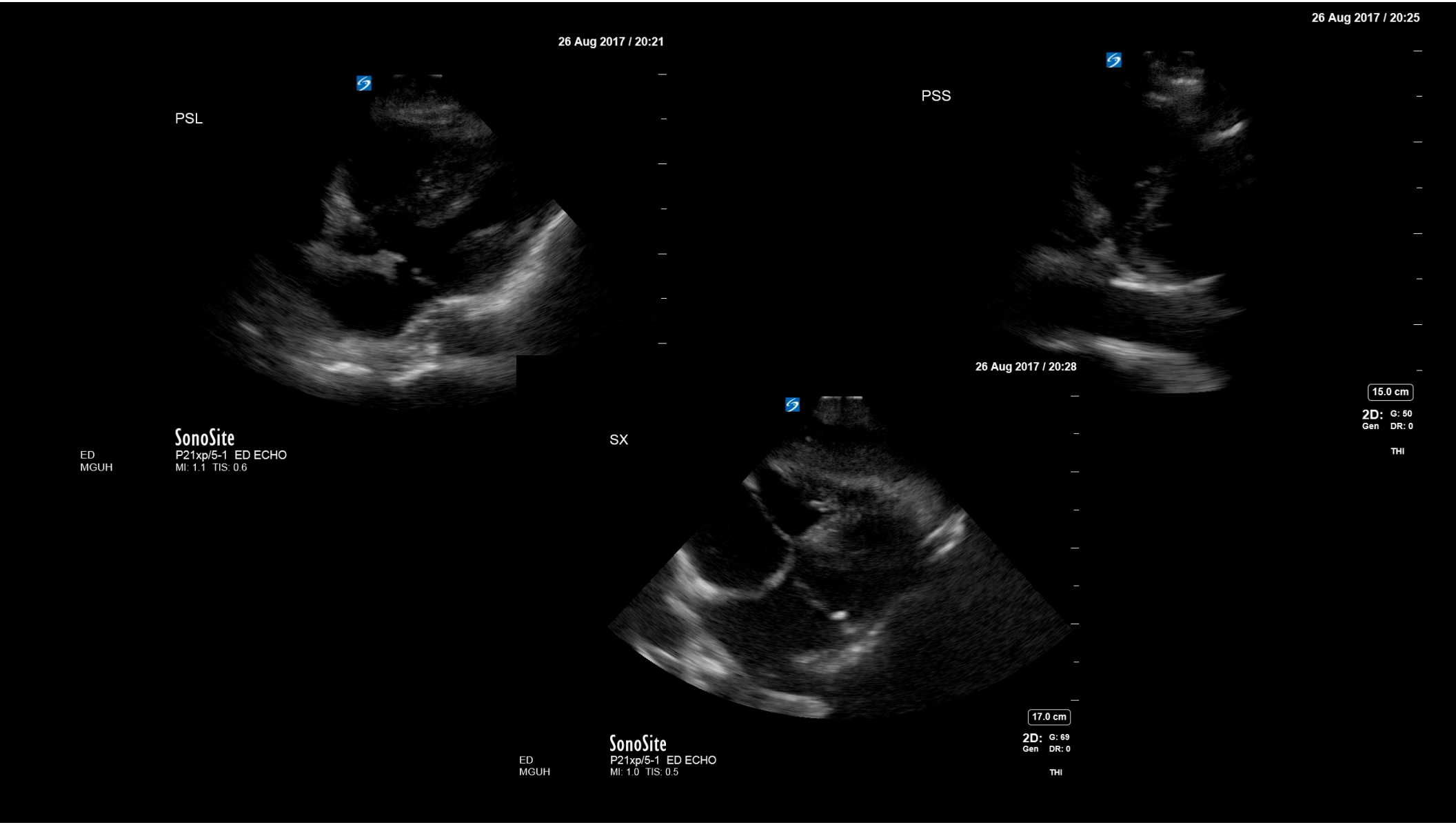
26 Aug 2017 / 20:21
PSL
SonoSite
ED
MGUH
P21xp/5-1 ED ECHO
MI: 1.1 TIS: 0.6
26 Aug 2017 / 20:25
PSS
15.0 cm
2D: G: 50
Gen DR: 0
THI
26 Aug 2017 / 20:28
SX
17.0 cm
2D: G: 69
Gen DR: 0
THI
SonoSite
ED
MGUH
P21xp/5-1 ED ECHO
MI: 1.0 TIS: 0.5

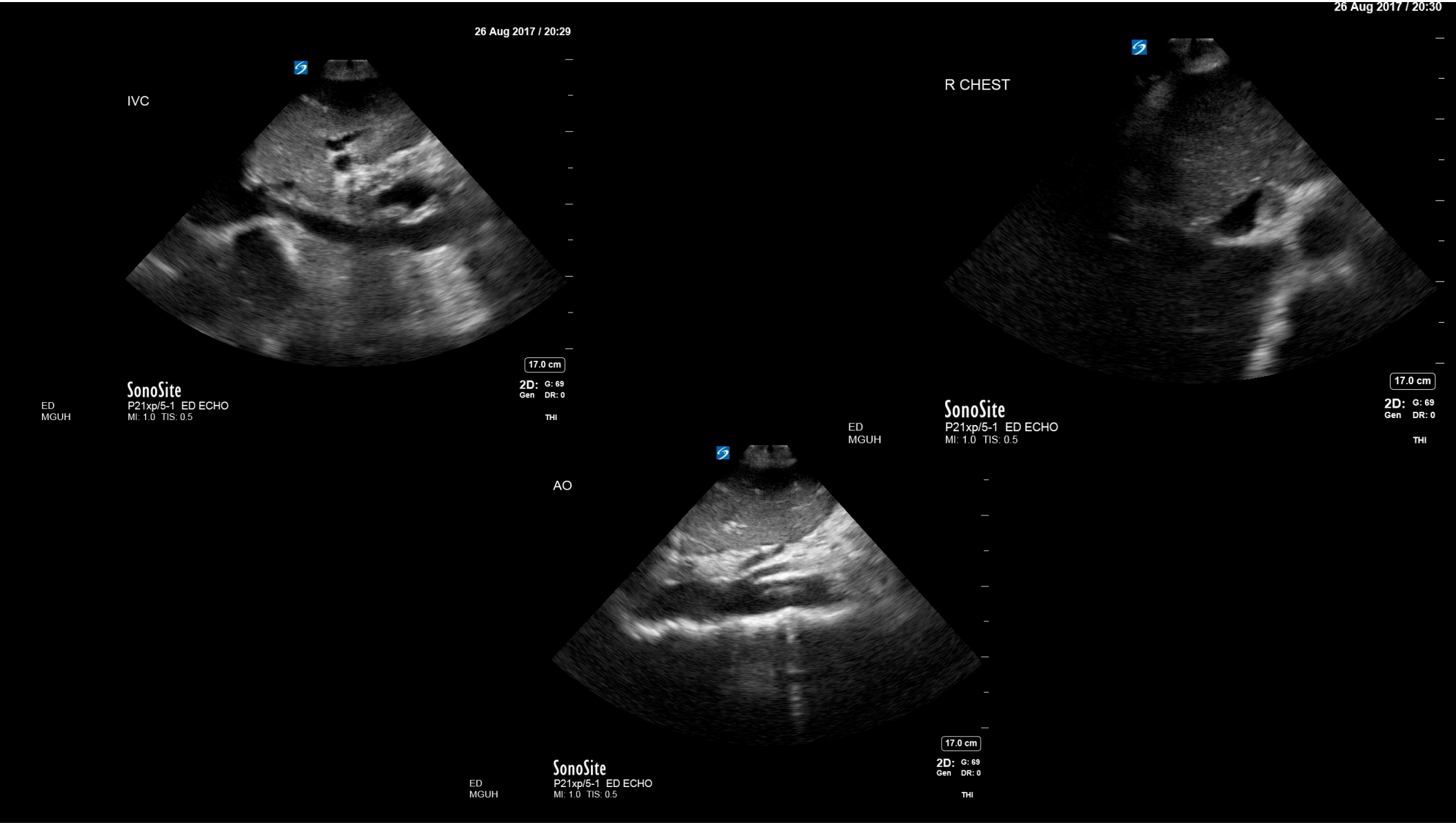
26 Aug 2017 / 20:29
IVC
17.0 cm
2D: G: 69
Gen DR: 0
THI
SonoSite
P21xp/5-1 ED ECHO
MI: 1.0 TIS: 0.5
ED
MGUH
26 Aug 2017 / 20:30
R CHEST
17.0 cm
2D: G: 69
Gen DR: 0
THI
SonoSite
P21xp/5-1 ED ECHO
MI: 1.0 TIS: 0.5
ED
MGUH
AO
17.0 cm
2D: G: 69
Gen DR: 0
THI
SonoSite
P21xp/5-1 ED ECHO
MI: 1.0 TIS: 0.5
ED
MGUH

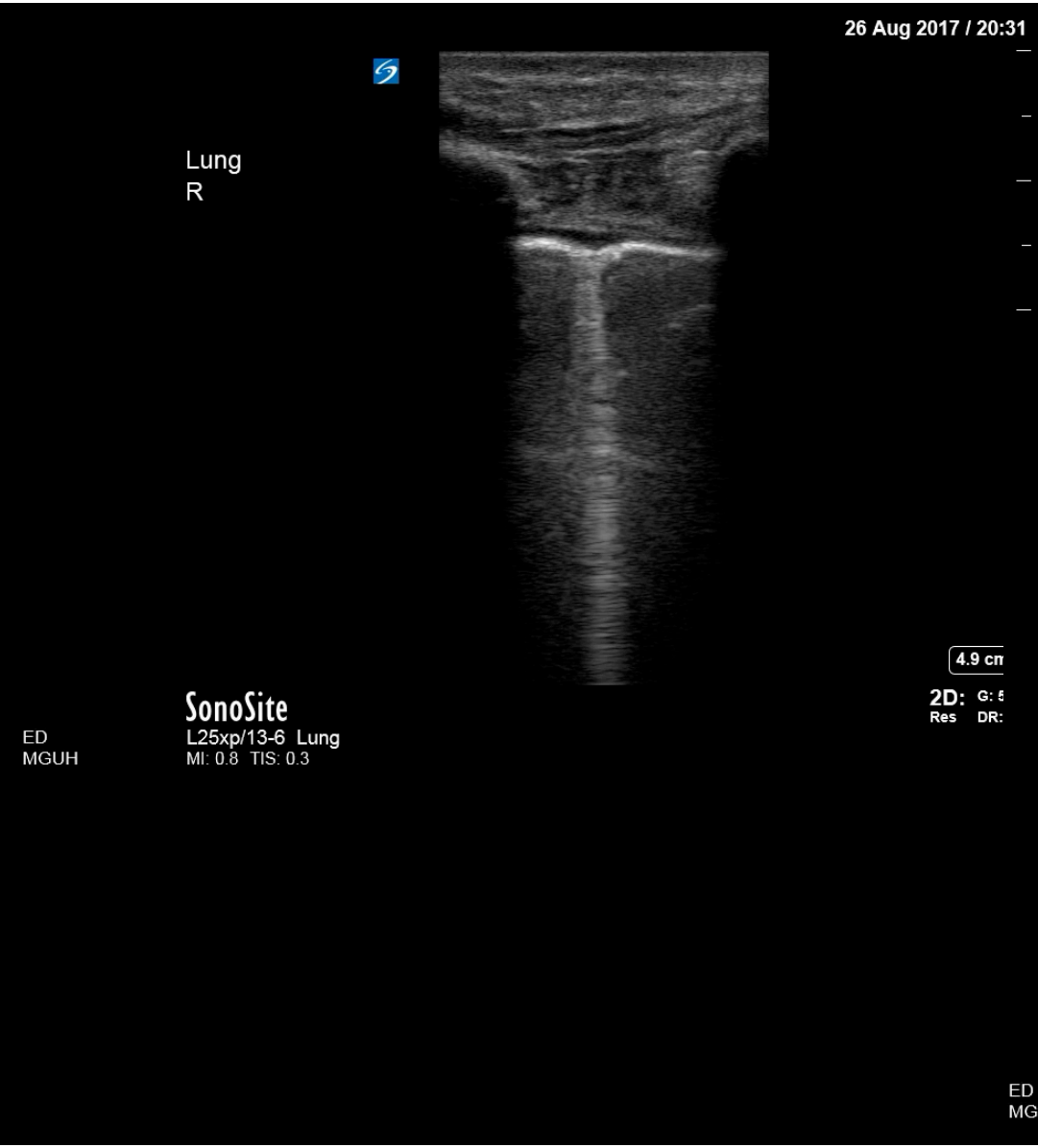
26 Aug 2017 / 20:31
Lung
R
4.9 cm
2D:
Res
SonoSite
L25xp/13-6 Lung
MI: 0.8 TIS: 0.3
ED
MGUH

26 Aug 2017 / 20:32
Lung
R
4.9 cm
2D: G: 50
Res DR: 0
SonoSite
L25xp/13-6 Lung
MI: 0.8 TIS: 0.3
ED
MGUH

26 Aug 2017 / 20:34

Left

SFV

SonoSite
L25xp/13-6 Venous
MI: 0.7 TIS: 0.2

ED
MGUH

26 Aug 2017 / 20:35

Left

Popliteal V

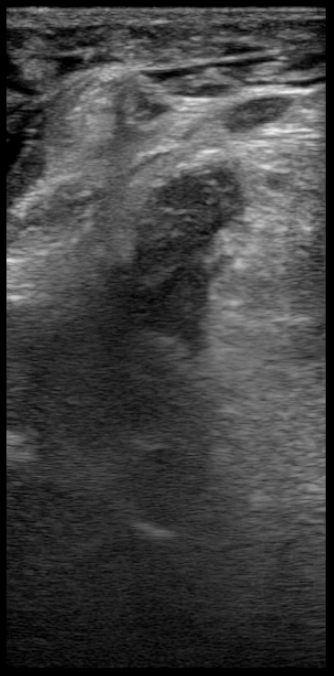

SonoSite
L25xp/13-6 Venous
MI: 0.6 TIS: 0.3

ED
MGUH

Table 1: RUSH protocol summary.

| RUSH exam | Hypovolemic shock | Cardiogenic shock | Obstructive shock | Distributive shock |
|---|---|---|---|---|
| Pump | Hypercontractile heart<br>Small heart size | Hypocontractile heart<br>Dilated heart size | Pericardial effusion, RV strain<br>Hypercontractile heart | Hypercontractile heart (early sepsis)<br>Hypocontractile heart (late sepsis) |
| Tank | Flat IVC<br>Flat IJV<br>Peritoneal fluid<br>Pleural fluid | Distended IVC<br>Distended IJV<br>Lung rockets<br>Pleural effusions, ascites | Distended IVC<br>Distended IJV<br>Absent lung sliding (PTX) | Normal/small IVC<br>Normal/small IJV<br>Pleural fluid (empyema)<br>Peritoneal fluid (peritonitis) |
| Pipes | AAA<br>Aortic dissection | Normal | DVT | Normal |

Seif D, Perera P, Mailhot T, Riley D, Mandavia D. Bedside ultrasound in resuscitation and the rapid ultrasound in shock protocol. Crit Care Res Pract. 2012;2012:503254. doi: 10.1155/2012/503254. Epub 2012 Oct 24. PMID: 23133747; PMCID: PMC3485910.

Table 2: Using the RUSH protocol to diagnose the type of shock.

| | Step no. 1 | Step no. 2 | Step no. 3 |
|---|---|---|---|
| Pump | Pericardial effusion:<br>(a) Effusion present?<br>(b) Signs of tamponade?<br>Diastolic collapse of R Vent +/− R Atrium? | Left ventricular contractility:<br>(a) Hyperdynamic?<br>(b) Normal?<br>(c) Decreased? | Right ventricular strain:<br>(a) Increased size of RV?<br>(b) Septal displacement<br>from right to left? |
| Tank | Tank volume:<br>(1) Inferior vena cava:<br>(a) Large size/small Insp collapse?<br>—CVP high—<br>(b) Small size/large Insp collapse?<br>—CVP Low—<br>(2) Internal jugular veins:<br>(a) Small or large? | Tank leakiness:<br>(1) E-FAST exam:<br>(a) Free fluid Abd/Pelvis?<br>(b) Free fluid thoracic cavity?<br>(2) Pulm edema:<br>Lung rockets? | Tank compromise:<br>Tension pneumothorax?<br>(a) Absent lung sliding?<br>(b) Absent comet tails? |
| Pipes | Abdominal aorta aneurysm:<br>Abd aorta > 3 cm? | Thoracic aorta aneurysm/dissection:<br>(a) Aortic root > 3.8 cm?<br>(b) Intimal flap?<br>(c) Thor aorta > 5 cm? | (1) Femoral vein DVT?<br>Noncompressible vessel?<br>(2) Popliteal vein DVT?<br>Noncompressible vessel? |

Seif D, Perera P, Mailhot T, Riley D, Mandavia D. Bedside ultrasound in resuscitation and the rapid ultrasound in shock protocol. Crit Care Res Pract. 2012;2012:503254. doi: 10.1155/2012/503254. Epub 2012 Oct 24. PMID: 23133747; PMCID: PMC3485910.

# References:


1. Seif D, Perera P, Mailhot T, Riley D, Mandavia D. Bedside ultrasound in resuscitation and the rapid ultrasound in shock protocol. Crit Care Res Pract. 2012;2012:503254. doi: 10.1155/2012/503254. Epub 2012 Oct 24. PMID: 23133747; PMCID: PMC3485910.

3. Perera P, Mailhot T, Riley D, Mandavia D. The RUSH exam: Rapid Ultrasound in SHock in the evaluation of the critically lll. Emerg Med Clin North Am. 2010 Feb;28(1):29-56, vii doi: 10.1016/j.emc.2009.09.010. PMID: 19945597.

2. Alpert EA. The ABCDs of ResUS - Resuscitation Ultrasound. Cureus. 2019 May 7;11(5):e4616. doi: 10.7759/cureus.4616. PMID: 31312543; PMCID: PMC6615576.

4. Estoos E, Nakitende D. Diagnostic Ultrasound Use In Undifferentiated Hypotension. 2021 May 1. In: StatPearls [Internet]. Treasure Island (FL): StatPearls Publishing; 2022 Jan–. PMID: 29763130.

5. Rahulkumar HH, Bhavin PR, Shreyas KP, Krunalkumar HP, Atulkumar S, Bansari C. Utility of Point-of-Care Ultrasound in Differentiating Causes of Shock in Resource-Limited Setup. J Emerg Trauma Shock. 2019 Jan-Mar;12(1):10-17. doi: 10.4103/JETS.JETS_61_18. PMID: 31057278; PMCID: PMC6496999.

6. Gonzalez JM, Ortega J, Crenshaw N, de Tantillo L. Rapid Ultrasound for Shock and Hypotension: A Clinical Update for the Advanced Practice Provider: Part 1. Adv Emerg Nurs J. 2020 Oct/Dec;42(4):270-283. doi: 10.1097/TME.0000000000000321. PMID: 33105180.

7. Dewar ZE, Wu J, Hughes H, Adnani A, Christiansen G, Ovedovitz L, Rittenberger JC. A comparison of handheld ultrasound versus traditional ultrasound for acquisition of RUSH views in healthy volunteers. J Am Coll Emerg Physicians Open. 2020 Nov 21;1(6):1320-1325. doi: 10.1002/emp2.12322. PMID: 33392539; PMCID: PMC7771775.

8. Ghane MR, Gharib MH, Ebrahimi A, Samimi K, Rezaee M, Rasouli HR, Kazemi HM. Accuracy of Rapid Ultrasound in Shock (RUSH) Exam for Diagnosis of Shock in Critically Ill Patients. Trauma Mon. 2015 Feb;20(1):e20095. doi: 10.5812/traumamon.20095. Epub 2015 Feb 20. PMID: 25825696; PMCID: PMC4362031.

9. Keikha M, Salehi-Marzijarani M, Soldoozi Nejat R, Sheikh Motahar Vahedi H, Mirrezaie SM. Diagnostic Accuracy of Rapid Ultrasound in Shock (RUSH) Exam; A Systematic Review and Meta-analysis. Bull Emerg Trauma. 2018 Oct;6(4):271-278. doi: 10.29252/beat-060402. PMID: 30402514; PMCID: PMC6215077.

# Web Resources for Further Learning:

Core Ultrasound:

https://www.coreultrasound.com/rush-exam/

ALiEM:

https://www.aliem.com/rush-protocol-rapid-ultrasound-shock-hypotension/

POCUS 101:

https://www.pocus101.com/rush-exam-ultrasound-protocol-step-by-step-guide/

# Questions?

Cory Wittrock
Emergency Ultrasound Director
UIHC Department of Emergency Medicine

cory-wittrock@uiowa.edu