What Your Voice Says About You

(and how to evaluate and treat voice disorders)

Hannah E. Reussner
DMU Graduate Student in Anatomy

Lee A. Reussner, M.D.
Director, Kansas Voice Center Lawrence, Kansas

We have no financial relationships to disclose, but do intend to discuss off-label use of a commercial product.

How Do We Develop Perceptions (differential diagnosis)?

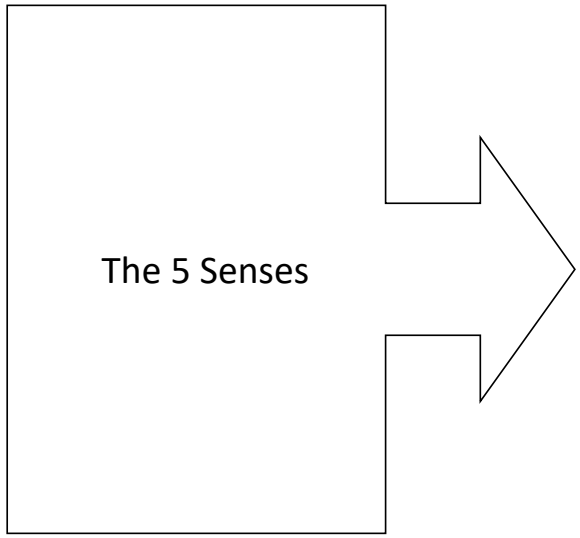

- Sight
- Sound
- Touch
- Smell
- Taste

Perception



Voice #1

- What is the diagnosis?
  - A . Normal voice for age
  - B. Vocal cord nodules
  - C. Improper technique/muscle tension
  - D. Vocal cord paralysis
  - E. Laryngeal cancer

Voice #2

- What is the diagnosis?
  - A. Normal voice for age
  - B. Vocal cord nodules
  - C. Improper technique/muscle tension
  - D. Vocal cord paralysis
  - E. Laryngeal cancer

Voice #3

- What is the diagnosis?
  - A . Normal voice for age
  - B. Vocal cord nodules
  - C. Improper technique/muscle tension
  - D. Vocal cord paralysis
  - E. Laryngeal cancer

Voice #4

- What is the diagnosis?
  - A . Normal voice for age
  - B. Vocal cord nodules
  - C. Improper technique/muscle tension
  - D. Vocal cord paralysis
  - E. Laryngeal cancer

Answers to Voice Quiz

- Voices #1 and #3 (female voice) – were the same patient
- 52 year old healthy school teacher, non smoker
- Diagnosis – muscle tension dysphonia
- Treated with speech therapy

Answers to Voice Quiz

- Voices #2 and #4 (male voice) were the same patient
- 74 year old male
- Diagnosis – vocal fold paralysis
- Treatment – medialization thyroplasty (surgical vocal cord implant)

Anatomy

- Lungs, thorax, abdomen - power source
- Larynx - oscillator
- Supraglottic vocal tract - resonator

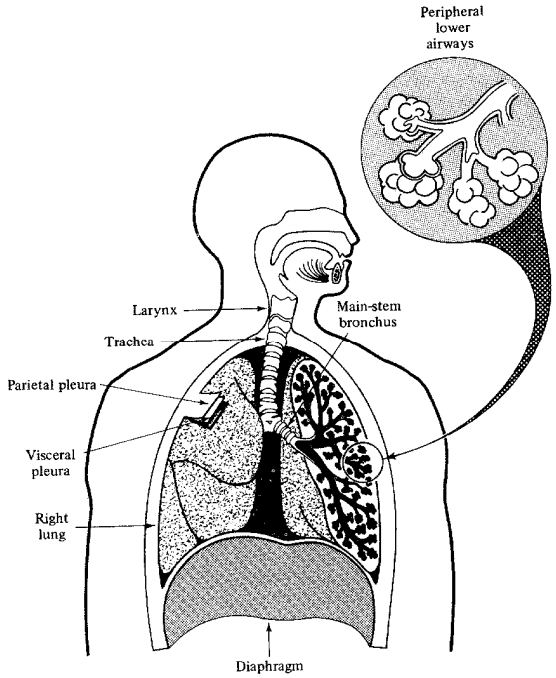

Anatomy of the Larynx - Cartilages

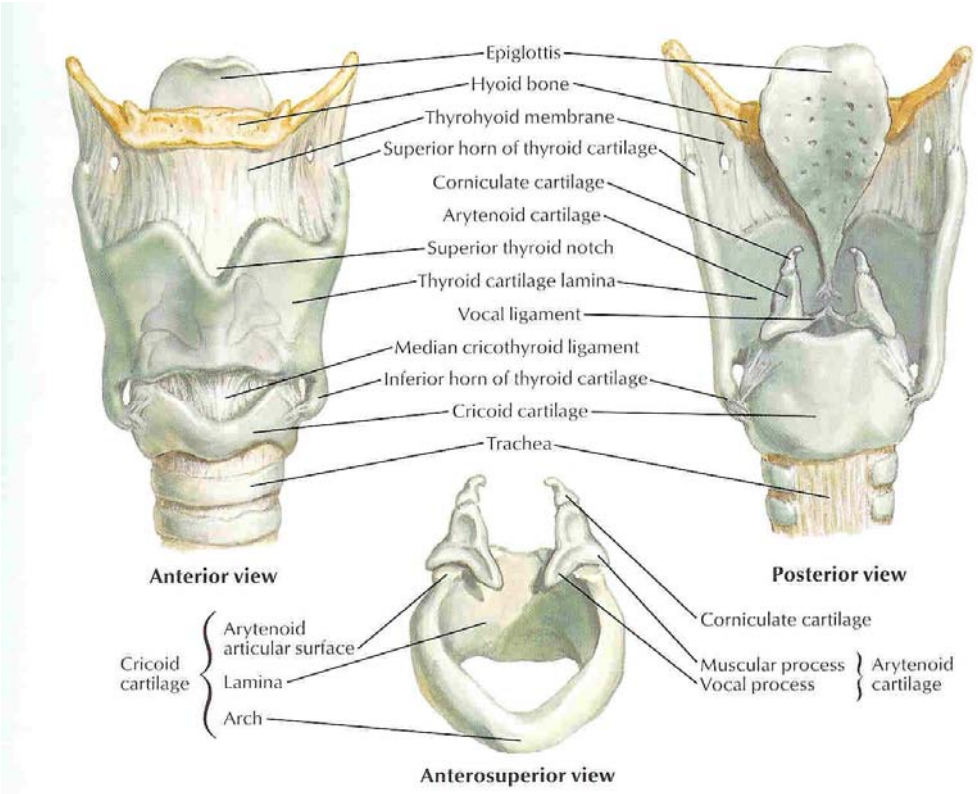

Anatomy of Larynx - Muscles

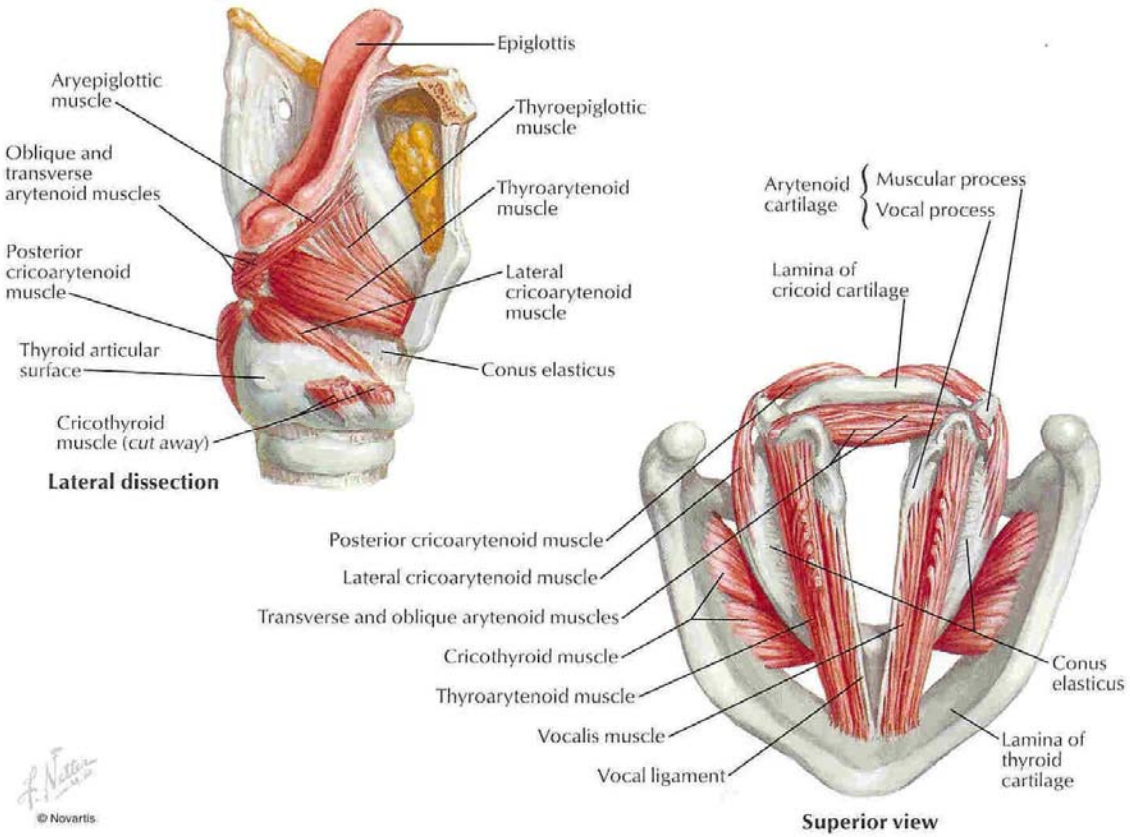

Anatomy of Larynx - Motion

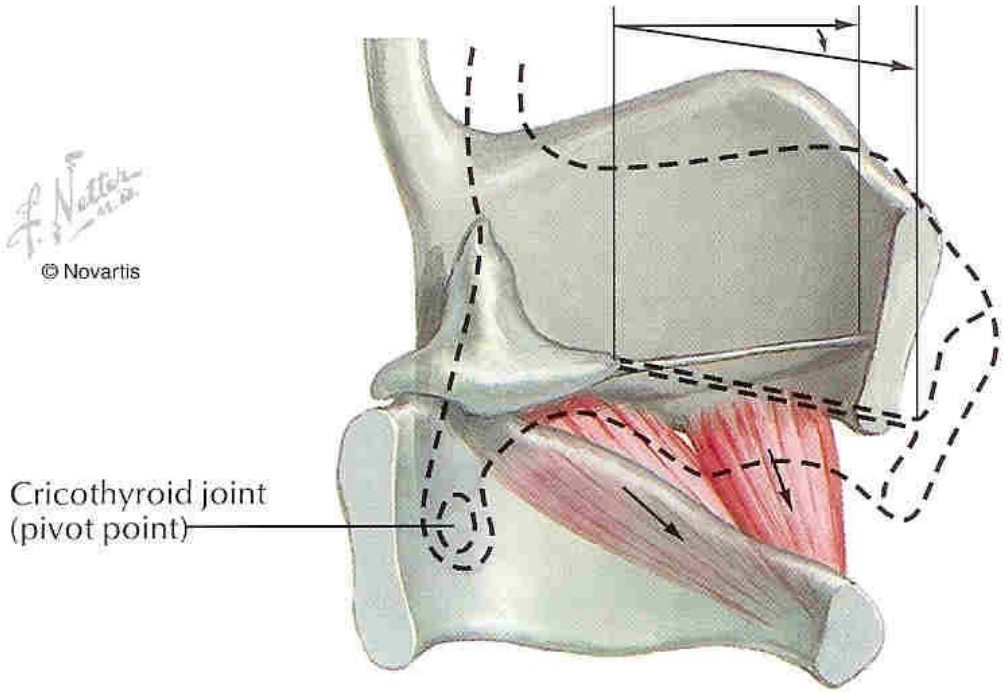

Anatomy of Larynx - Nerves

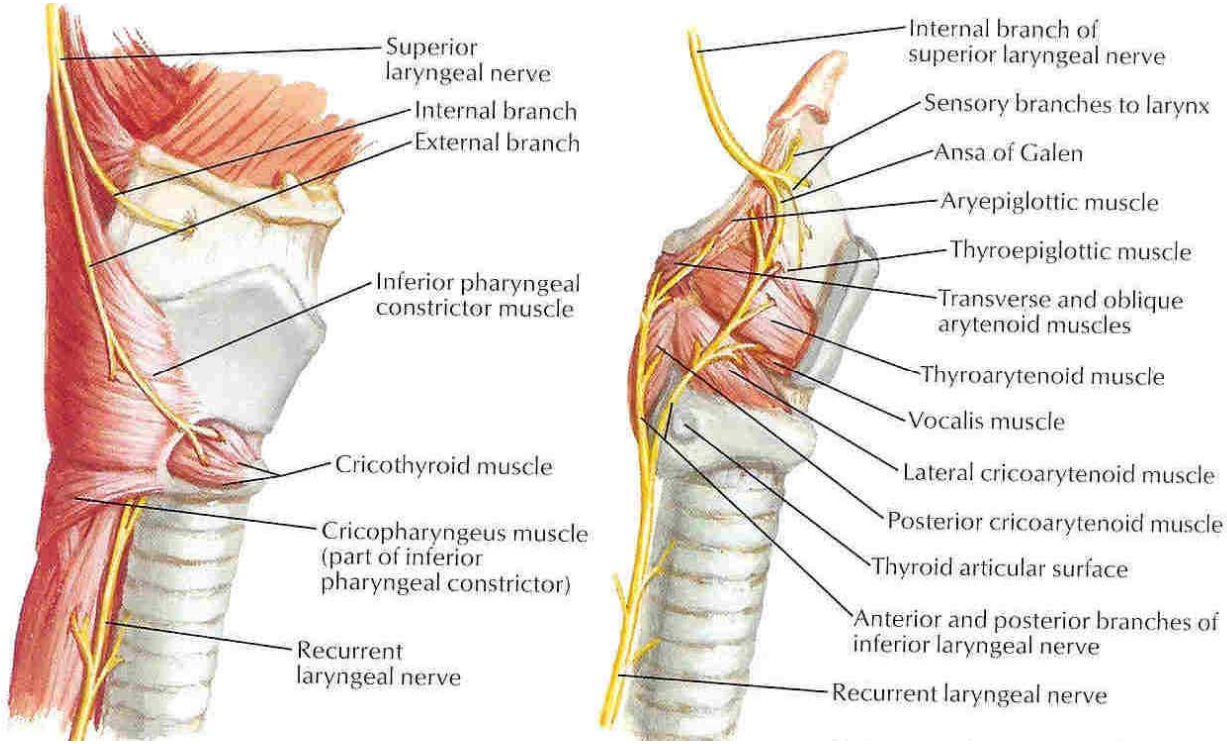

Functions of Larynx

- Passage for Respiration
- Prevents Aspiration
- Phonation
- Allows Stabilization of Thorax

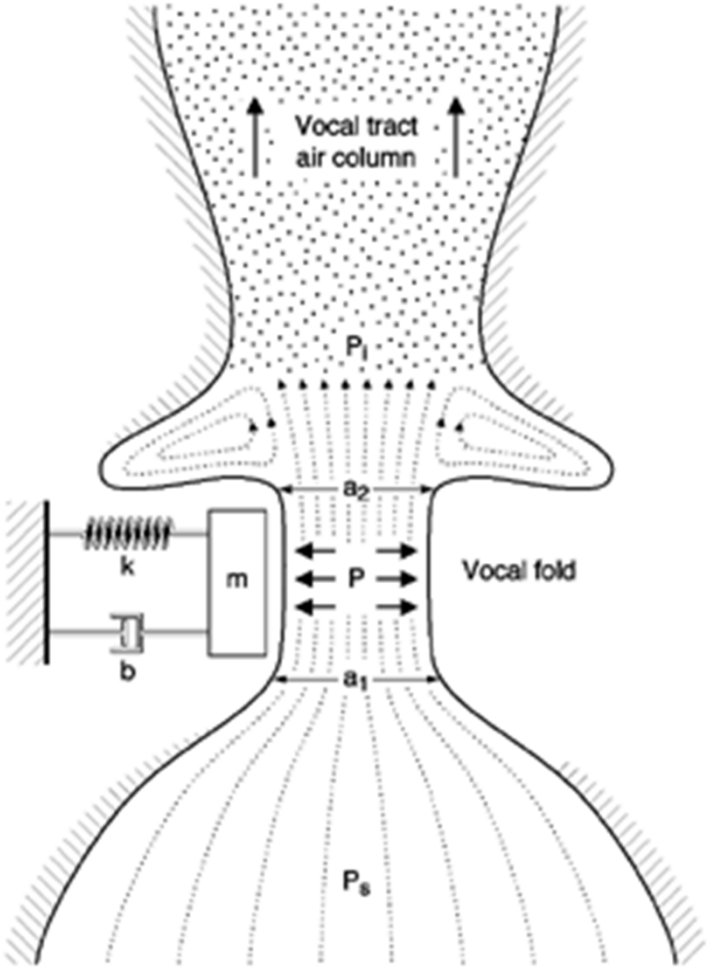
Vocal tract
air column
P_l
a_2
k
m
P
Vocal fold
b
a_1
P_s

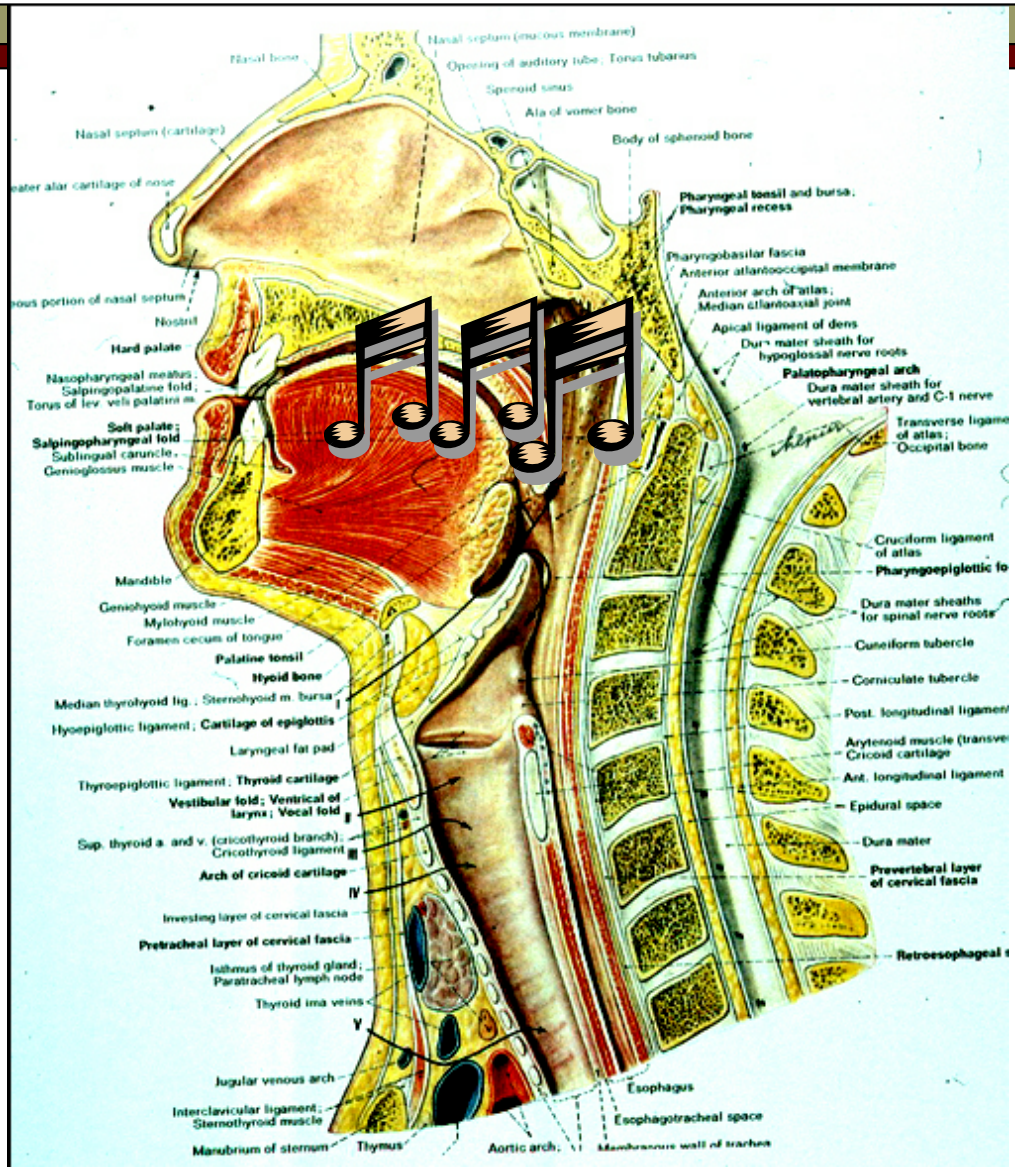
Nasal septum (mucous membrane)
Nasal bone
Opening of auditory tube; Torus tubarius
Sphenoid sinus
Ala of vomer bone
Nasal septum (cartilage)
Body of sphenoid bone
Pharyngeal tonsil and bursa; Pharyngeal recess
Pharyngobasilar fascia
Anterior atlantooccipital membrane
Anterior arch of atlas; Median atlantoaxial joint
Apical ligament of dens
Dura mater sheath for hypoglossal nerve roots
Palatopharyngeal arch
Dura mater sheath for vertebral artery and C-1 nerve
Transverse ligament of atlas; Occipital bone
Nostril
Hard palate
Nasopharyngeal meatus; Salpingopalatine fold; Torus of levator veli palatini m.
Soft palate; Salpingopharyngeal fold
Sublingual caruncle; Genioglossus muscle
Cruciform ligament of atlas
Pharyngoepiglottic fold
Mandible
Geniohyoid muscle
Mylohyoid muscle
Foramen cecum of tongue
Dura mater sheaths for spinal nerve roots
Cuneiform tubercle
Palatine tonsil
Hyoid bone
Corniculate tubercle
Median thyrohyoid lig.; Sternohyoid m. bursa
Hyoepiglottic ligament; Cartilage of epiglottis
Post. longitudinal ligament
Laryngeal fat pad
Arytenoid muscle (transverse); Cricoid cartilage
Thyroepiglottic ligament; Thyroid cartilage
Ant. longitudinal ligament
Vestibular fold; Ventrical of larynx; Vocal fold
Epidural space
Sup. thyroid a. and v. (cricothyroid branch); Cricothyroid ligament
Dura mater
Arch of cricoid cartilage
Prevertebral layer of cervical fascia
Investing layer of cervical fascia
Pretracheal layer of cervical fascia
Retroesophageal
Isthmus of thyroid gland; Paratracheal lymph node
Thyroid ima veins
Jugular venous arch
Esophagus
Interclavicular ligament; Sternothyroid muscle
Esophagotracheal space
Manubrium of sternum
Thymus
Aortic arch

When the voice does not sound right

- Is it technique? - instruction and possible speech pathology
- Is it the instrument? – voice team evaluation
- Is it both?

Team Approach

- Laryngologist
- Speech-Language Pathologist
- Singing-Voice Specialist / Vocal Teacher
- Acting-Voice Specialist / Speaking Coach
- Other Clinicians (Nurses, Psychologists)
- Other Physicians (Pulmonologists, Allergists, Neurologists)

Instruments Used in Diagnosis of Voice Disorders

- Head and Neck Exam Tools
- Videostroboscope
- Electroglottography
- Pulmonary Function Tests
- Acoustic Analysis / Phonatory Ability Tests
- Electromyography
- Imaging
- The Human Ear and Eye

Laryngeal Videostroboscopy

- Purpose - Detect Laryngeal Abnormalities
  -magnification

  -slow motion effect

  -recording
- Protocol/Observations Made
  (fundamental frequency, symmetry, periodicity, glottic closure, amplitude, mucosal wave, mass lesions, muscular function, mucosal appearance)

Voice Disorders

- Functional
- Infectious
- Inflammatory
- Medication effects
- Traumatic
- Benign lesion
- Neurologic
- Neoplasms-malignant

Look and Listen!

- 31 year old healthy female
- 8 month history of squeaky voice
- Has seen multiple physicians
- On disability



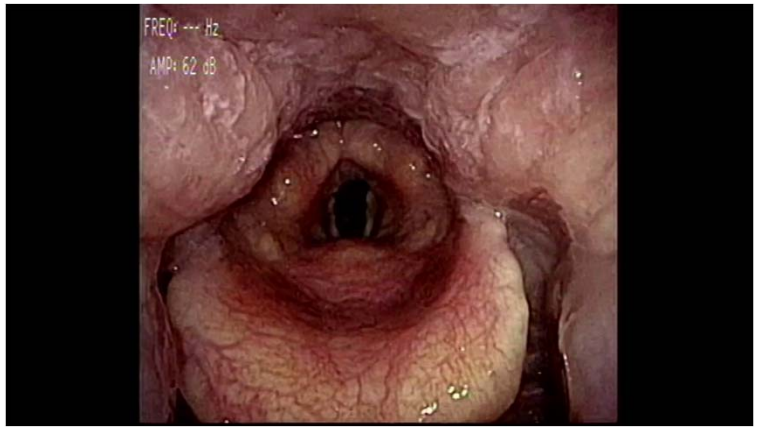

Functional Voice Disorders

- No anatomic or neurologic abnormality
- Can take many forms
- Muscle tension dysphonia, hypophonia, aphonia, stuttering, etc.
- Treatment – speech pathologist

Red Flags for Functional Speech and Voice Disorders

•Suggestibility
•Distractibility
•Acute onset
•Variable severity during different speech examination activities
•Paradoxical increased muscle contraction with fatigue
•Potential for rapid reversibility or improvement of symptoms
•Denial or indifference to abnormal speech/voice

Infectious

Laryngitis

Laryngitis

- Usually viral
- Relative voice rest
- Voice lessons - technical adjustments
- Hydration
- Expectorant (guaifenesin)
- Rarely antibiotics, steroids
- Sprays rarely

Infectious

- Middle aged woman
- Hoarse for months
- Moderate sore throat
- Uses steroid inhalers for severe asthma

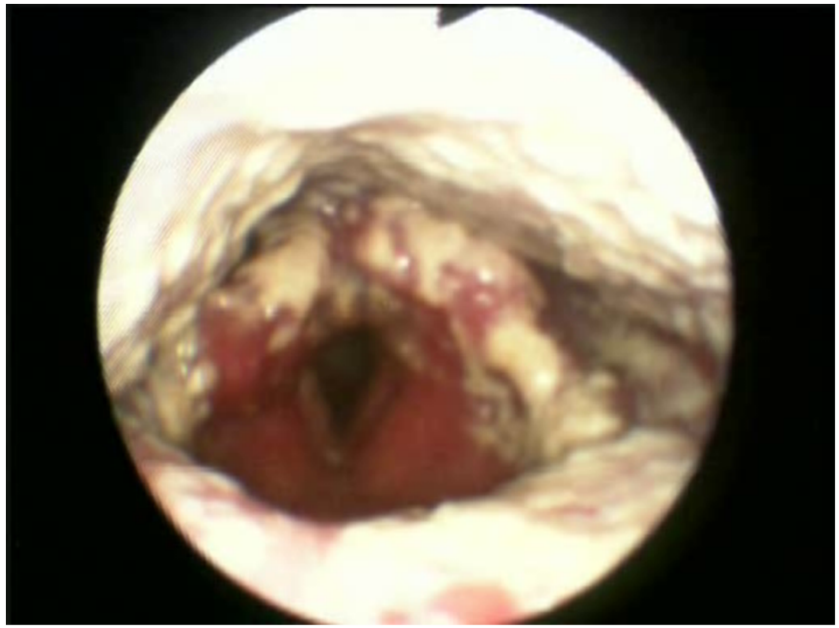

Laryngeal Yeast Infection

- Risks include: diabetes, inhaled steroid use, antibiotics
- Treat with mouth rinses after inhalers, antifungal medications

Infectious

- Healthy male with increasing hoarseness over months
- Had 2 separate laryngeal operations years ago to remove “polyps”
- Voice has never been completely normal

Laryngeal Papilloma (Recurrent Respiratory Papillomas)

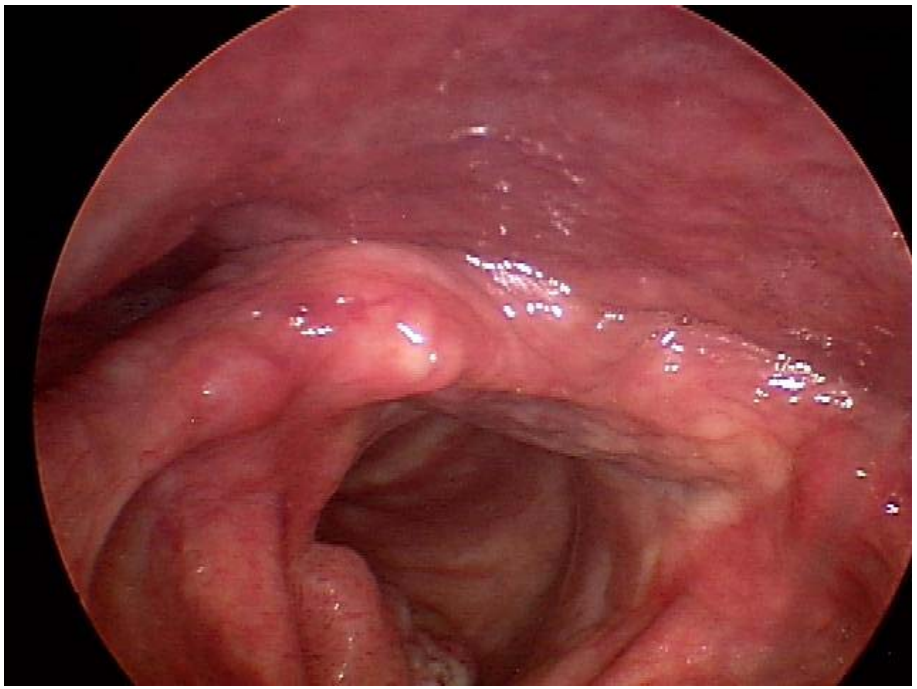

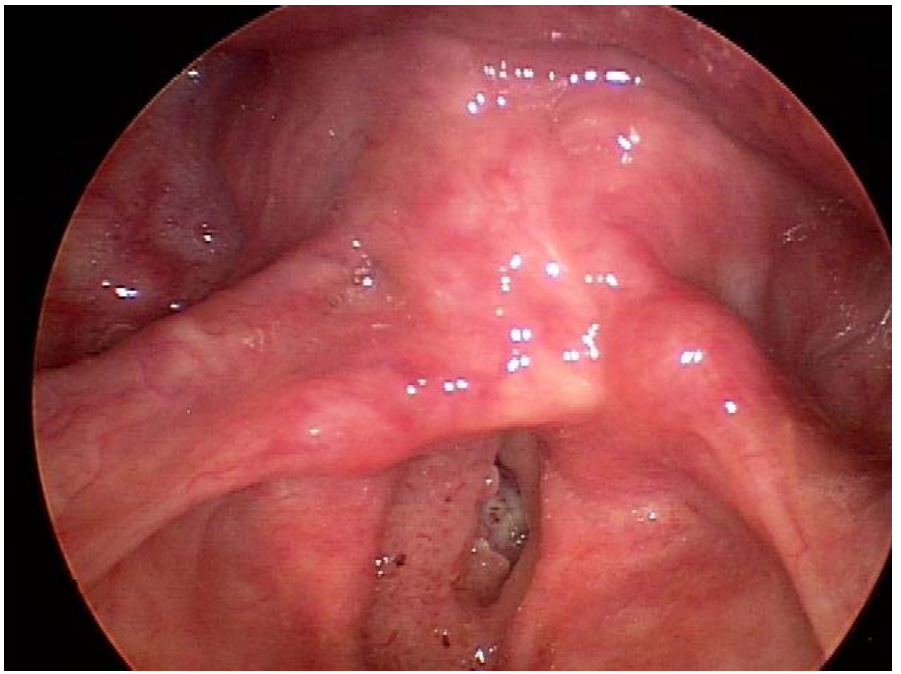

RRP

Recurrent Respiratory Papillomas

- Most common benign laryngeal neoplasm in children – though not uncommon in adults
- Caused by HPV 6 or 11
- Can get at birth or acquire later
- Can be latent for years
- Average child – 20 operations

RRP

Recurrent Respiratory Papillomas

- Treatment surgical
- Cidofovir
- Indol-3-carbinole
- Many other meds have been tried
- Gardasil vaccine

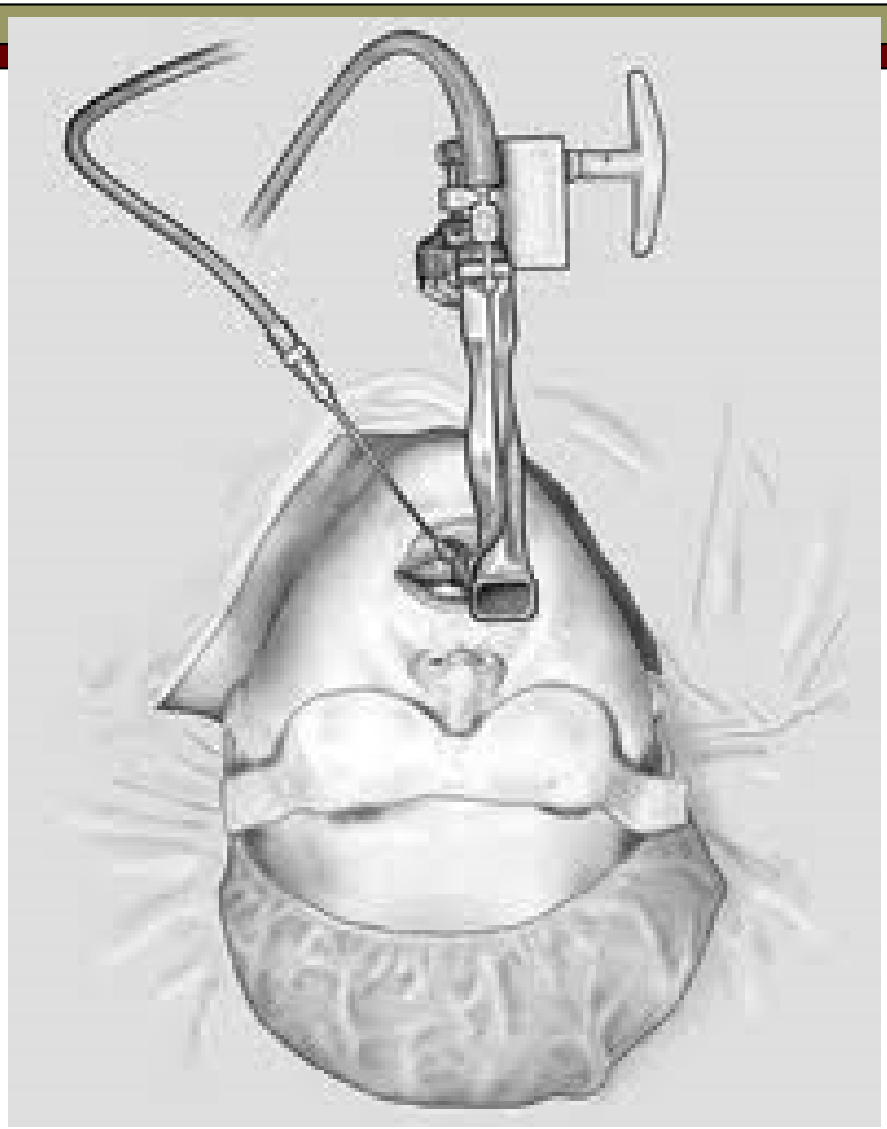

Infectious

Papilloma

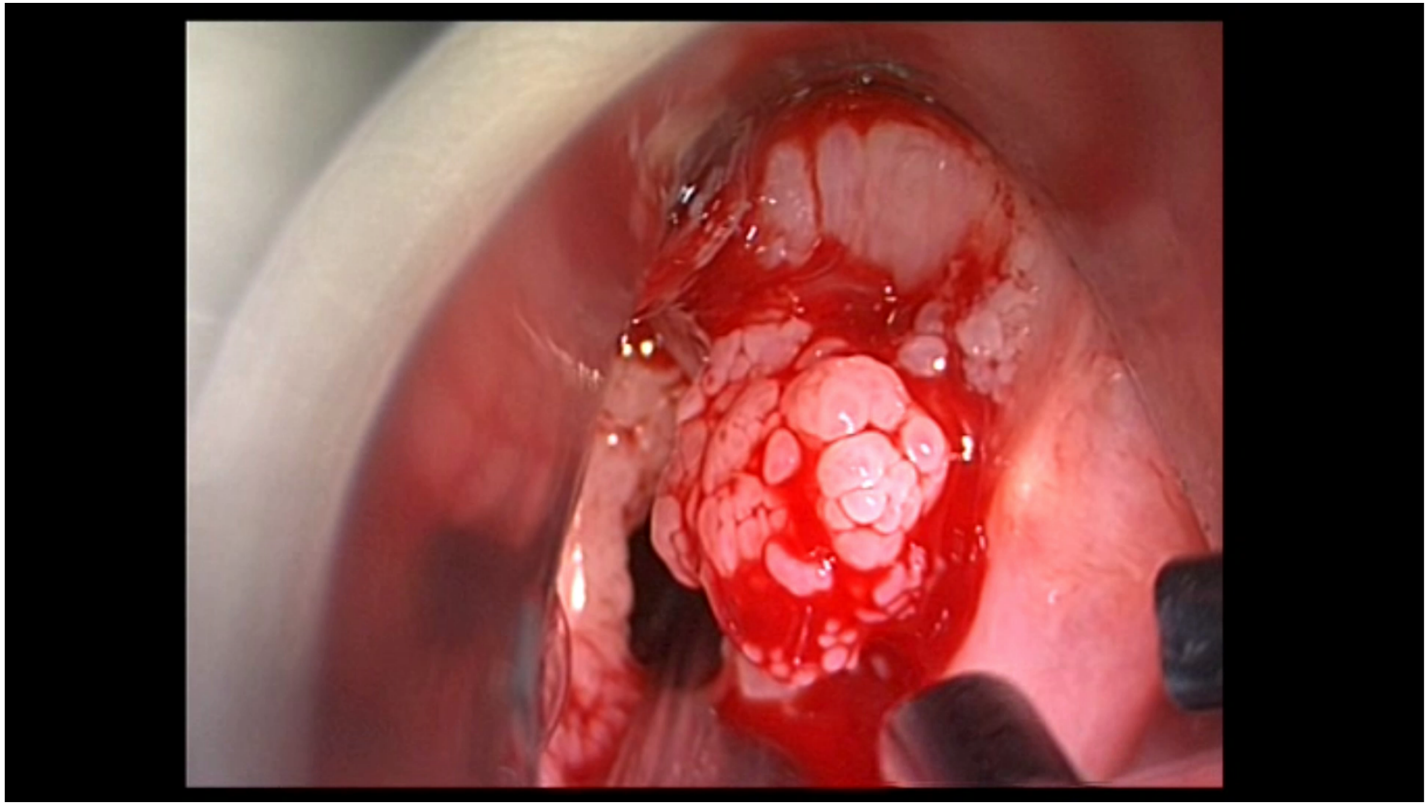

Voice Disorders

- Functional
- Infectious
- Inflammatory
- Medication effects
- Traumatic
- Benign lesion
- Neurologic
- Neoplasms-malignant

Inflammatory

- Reflux
- Reinke’s edema

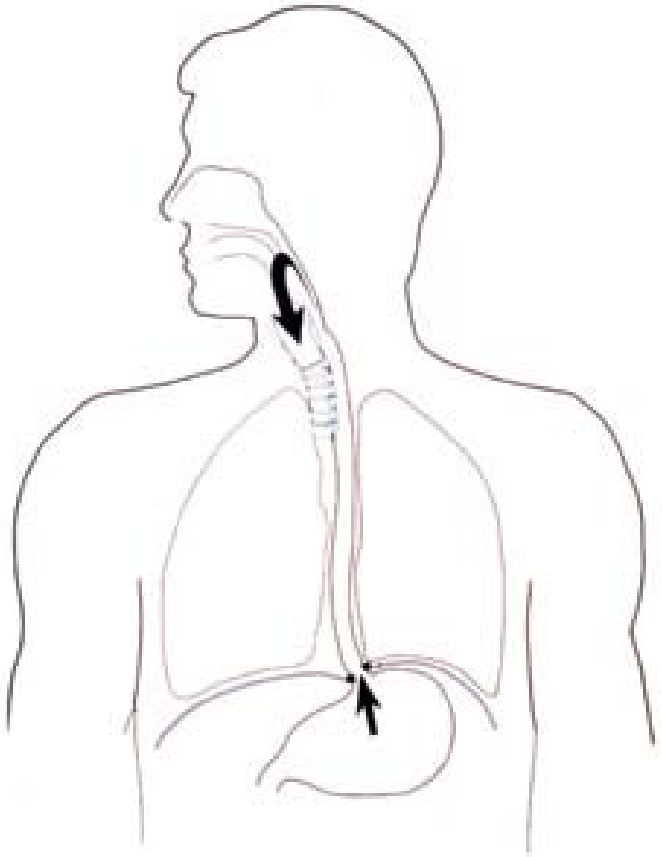

LPRD:

Backflow of gastric contents from the stomach into the laryngopharynx.

What's in a name?

- GER [gastroesophageal reflux]
- GERD [gastroesophageal reflux disease]
- GEPRD [g.e. pulmonary reflux disease]
- GELAPURD [g.e. laryngeal pulm. ref. dis]
- ATYRD [atypical reflux disease]
- EXERD [extraesophageal reflux disease]
- LPRD laryngopharyngeal reflux disease

Symptoms of LPRD

- Chronic dysphonia
- Intermittent dysphonia
- Vocal fatigue
- Voice breaks
- Chronic throat clearing
- Excessive throat mucus
- "Postnasal drip"
- Chronic cough
- Dysphagia
- Globus

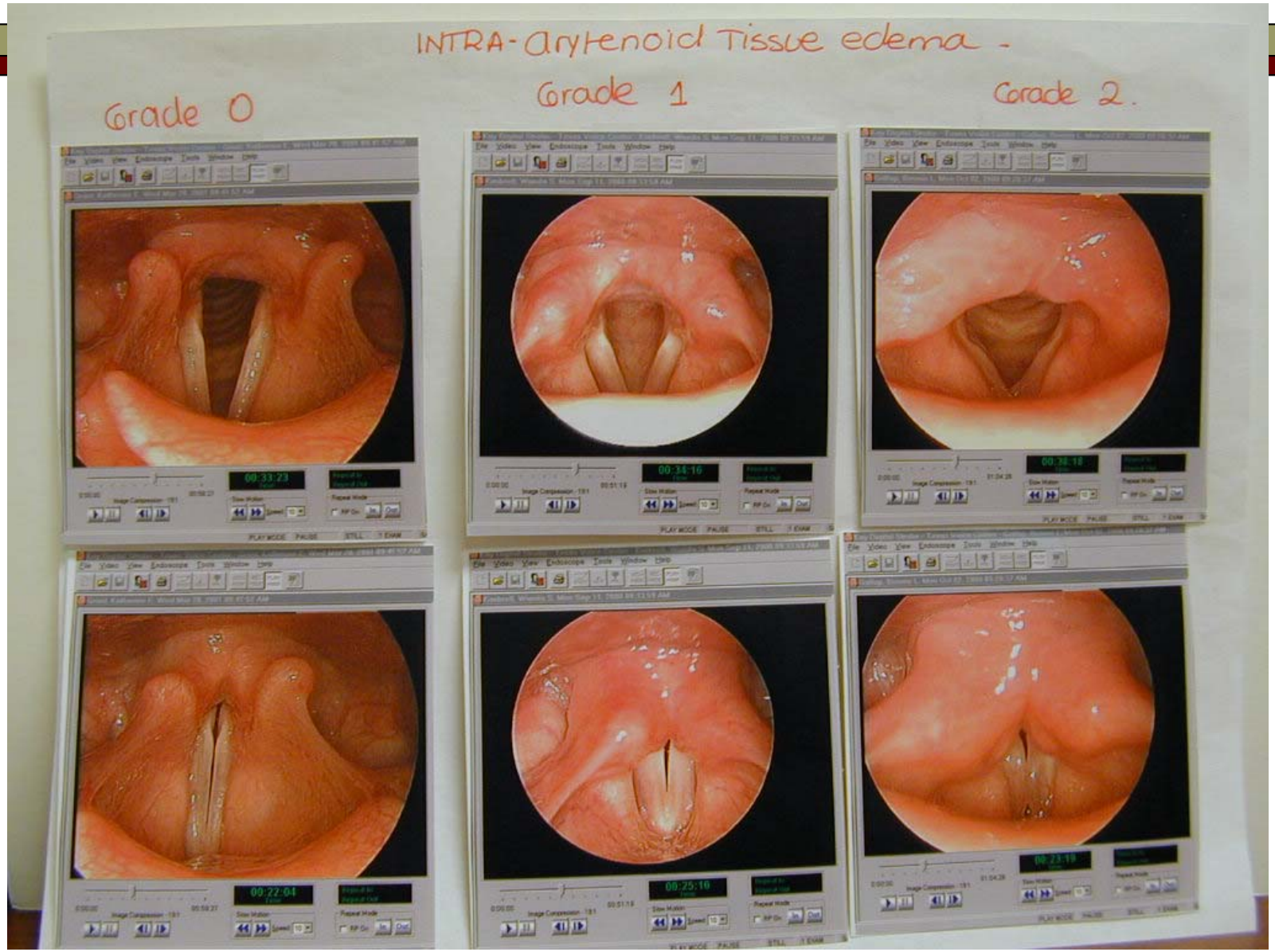
INTRA-arytenoid Tissue edema -
Grade 0
Grade 1
Grade 2.

24 Hour pH probe or Impedance testing

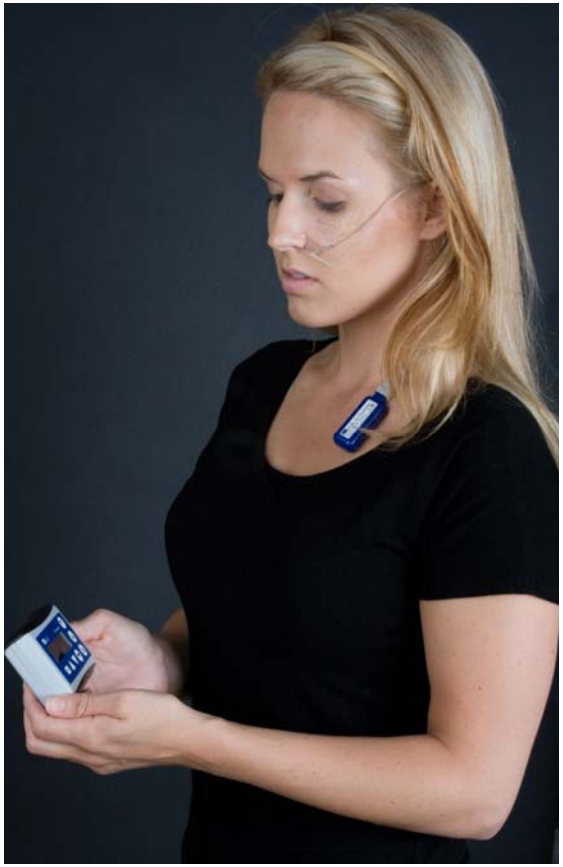

Reflux Treatment

- Dietary changes
- Medications such as: Nexium, Prevacid, Prilosec, Protonix, Aciphex, Zantac, Pepsid, etc. (Used to decrease acidity of refluxate)
- Occasionally surgery

Reflux

… after 2 months of omeprazole

50 Year Old

- Voice seems to be worsening over 10 years
- Starting to have difficulty breathing
- Long time smoker

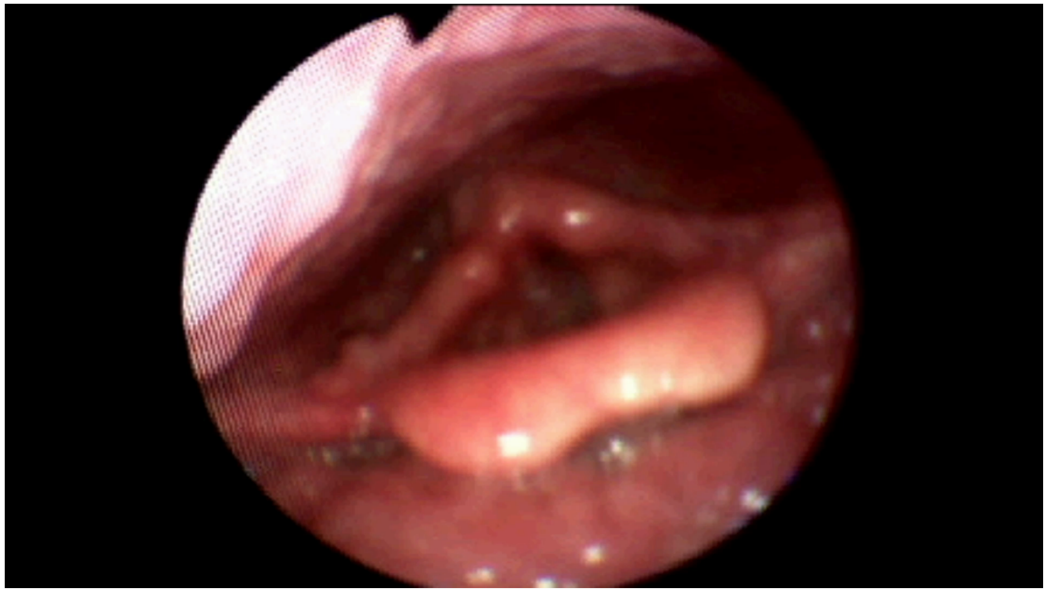

Is Female!

Reinke’s Edema post surgery

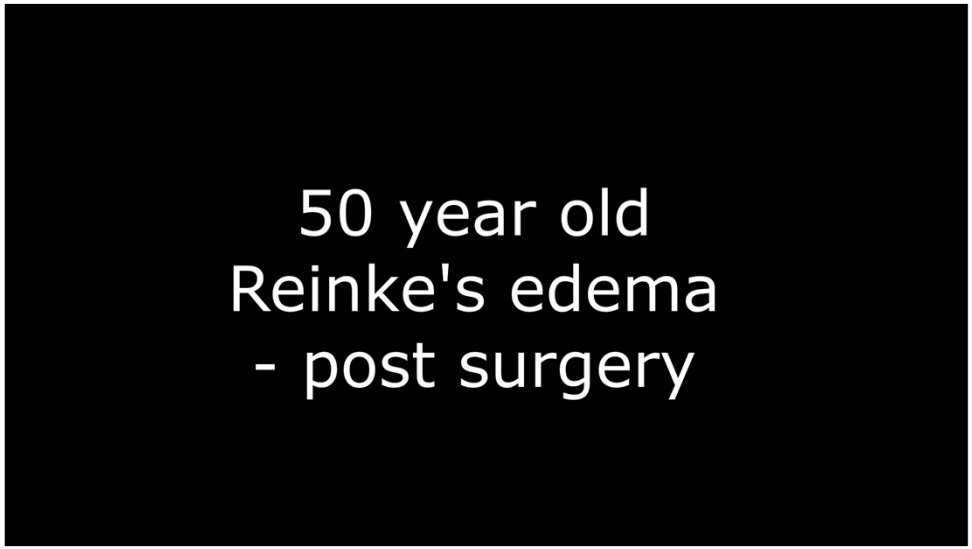

- Nearly always due to smoking
- Can be treated surgically
- Will likely return if smoking continues

Voice Disorders

- Functional
- Infectious
- Inflammatory
- Medication effects
- Traumatic
- Benign lesion
- Neurologic
- Neoplasms-malignant

Medication effects - Inhalers

- Steroid inhalers are most problematic
- All oral inhalers can cause hoarseness and dry mouth – should gargle after use. Steroids carry higher incidence of hoarseness and may cause candida infection
- Nasal sprays are safe for the voice

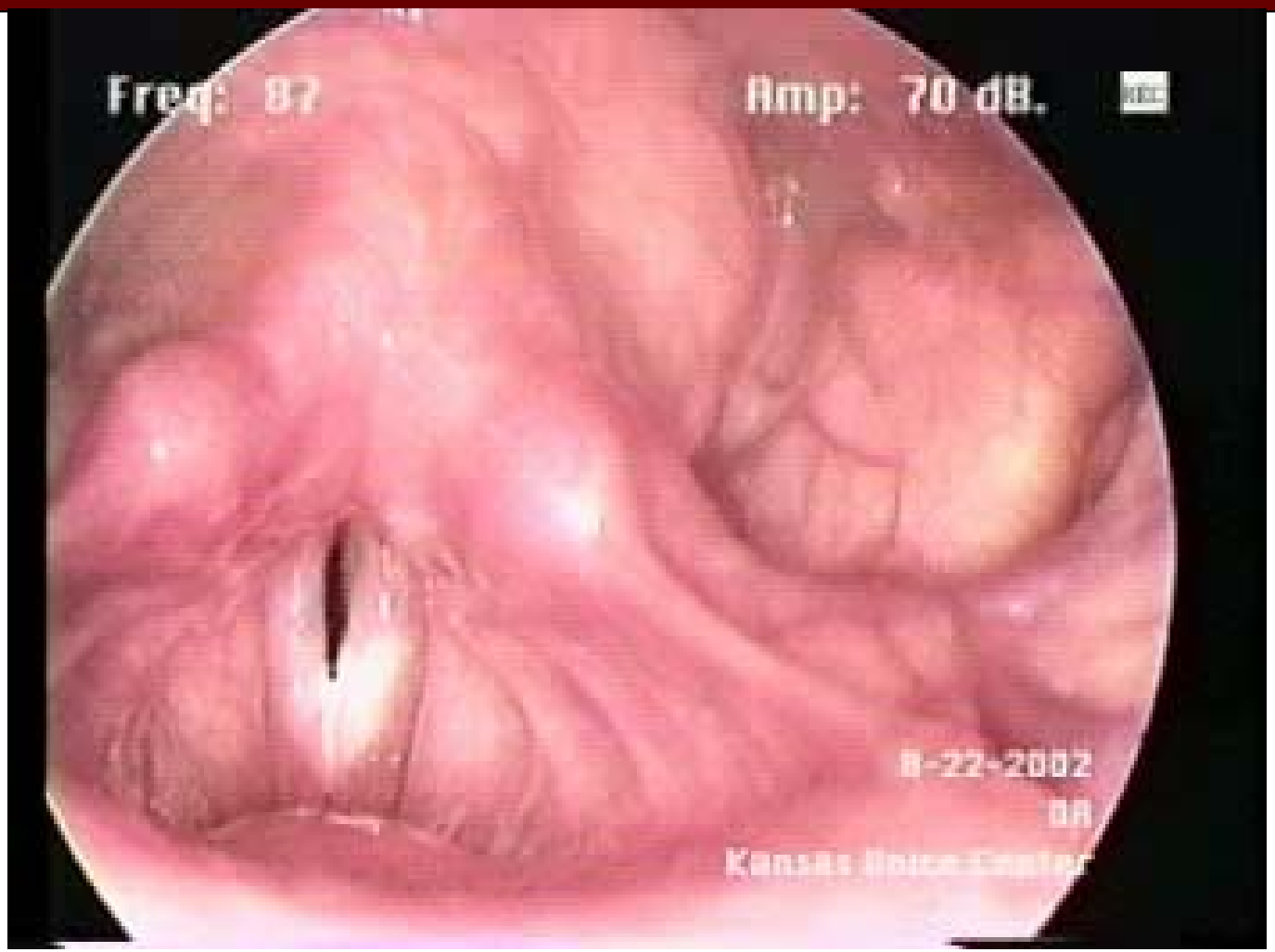
Freq: 87
Amp: 70 dB.
8-22-2002
BR

Analgesics

- Used for pain, inflammation, antiplatelet effect etc.
- Aspirin, ibuprofen, acetaminophen, etc.

Aspirin may predispose to vocal hemorrhage.
Ibuprofen less likely to cause this effect.
Acetaminophen does not cause bleeding.

See PDR for each medication

Traumatic/Medication Related hemorrhage

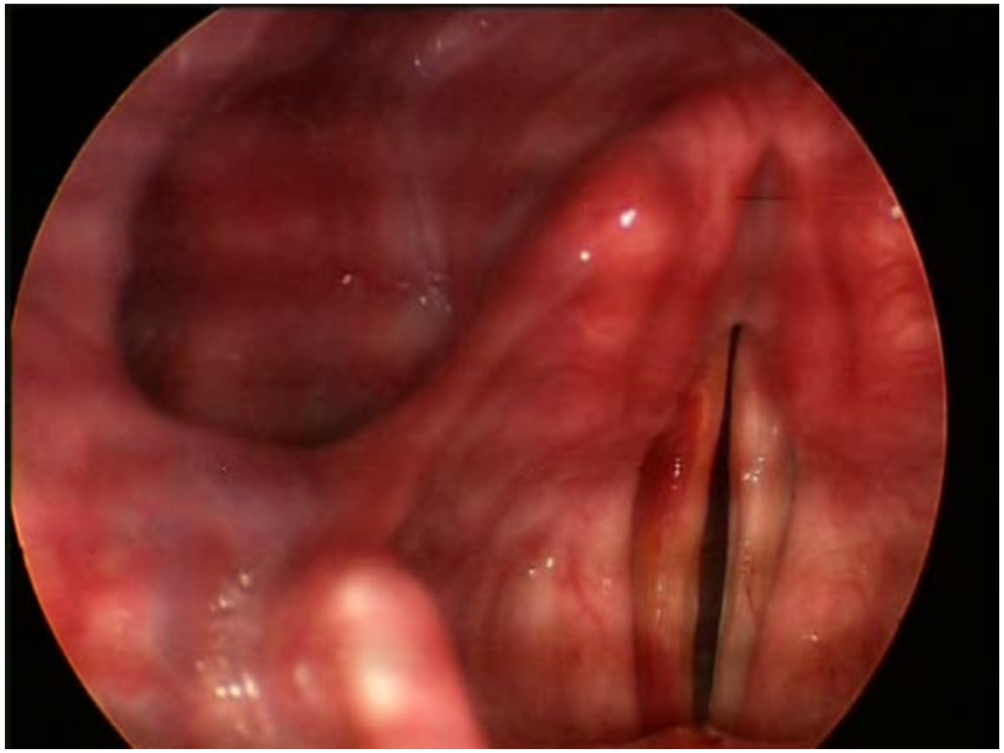

Traumatic posterior web

Voice Disorders

- Functional
- Infectious
- Inflammatory
- Medication effects
- Traumatic
- Benign lesion
- Neurologic
- Neoplasms-malignant

Benign Lesions

Nodules - “singer’s nodes”

- Bilateral
- Young males, adult females
- Nodes or calluses
- Difficulty with high pitches
- Usually nonsurgical

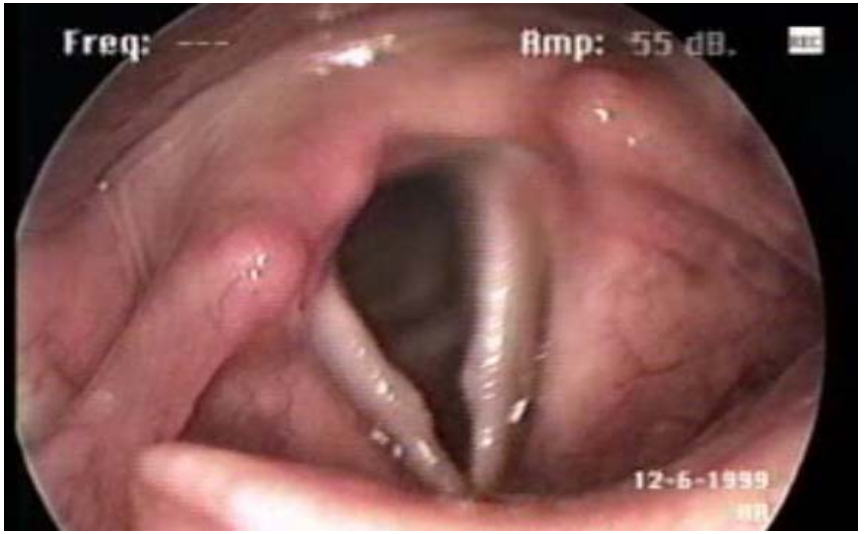

Benign Lesions

Polyps

- Unilateral
- Possible vocal “event”
- Fleshy
- Voice quality can vary
- Sometimes surgical

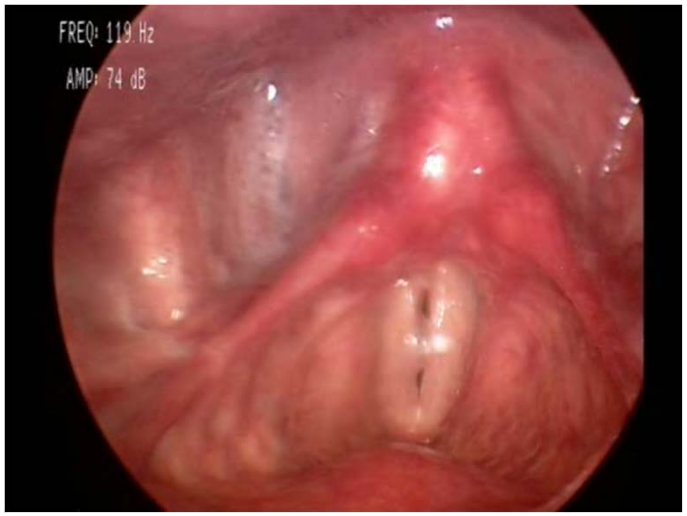

Benign Lesions

Cysts

- Unilateral
- Different causes, fluid filled
- Decreased mucosal wave
- Often surgical

Voice Disorders

- Functional
- Infectious
- Inflammatory
- Medication effects
- Traumatic
- Benign lesion
- Neurologic
- Neoplasms-malignant

Neurologic

Tremor

- Often older age – A similar spasmodic voice can happen with Spasmodic Dysphonia in younger individuals
- Regular, rhythmic contractions
- Sometimes head tremor
- Treat with therapy, meds, Botox

Our Initial Male Test Patient – Vocal Fold Paralysis

Vocal Fold Paralysis
Why is it a problem?

- Poor voice
  - Soft, effortful, difficult to project
- Aspiration concerns

Causes of Paralysis

- Congenital
- Infectious
- Traumatic
- Neoplastic
- Inflammatory
- Idiopathic

Thyroid surgery
Chest Surgery
Carotid/C spine procedures
Intubation

Thyroid tumors
Lung tumors

Treatment

- None
- Speech therapy
- Short term – Vocal cord injections: gelfoam, collagen, fat, cymetra, voice gels
- Long term – thyroplasty (multiple materials), for medialization of vocal cord
- Treatment for bilateral paralysis – trach, botox, arytenoidectomy, posterior cordotomy, reinnervation

Thyroplasty – Type I

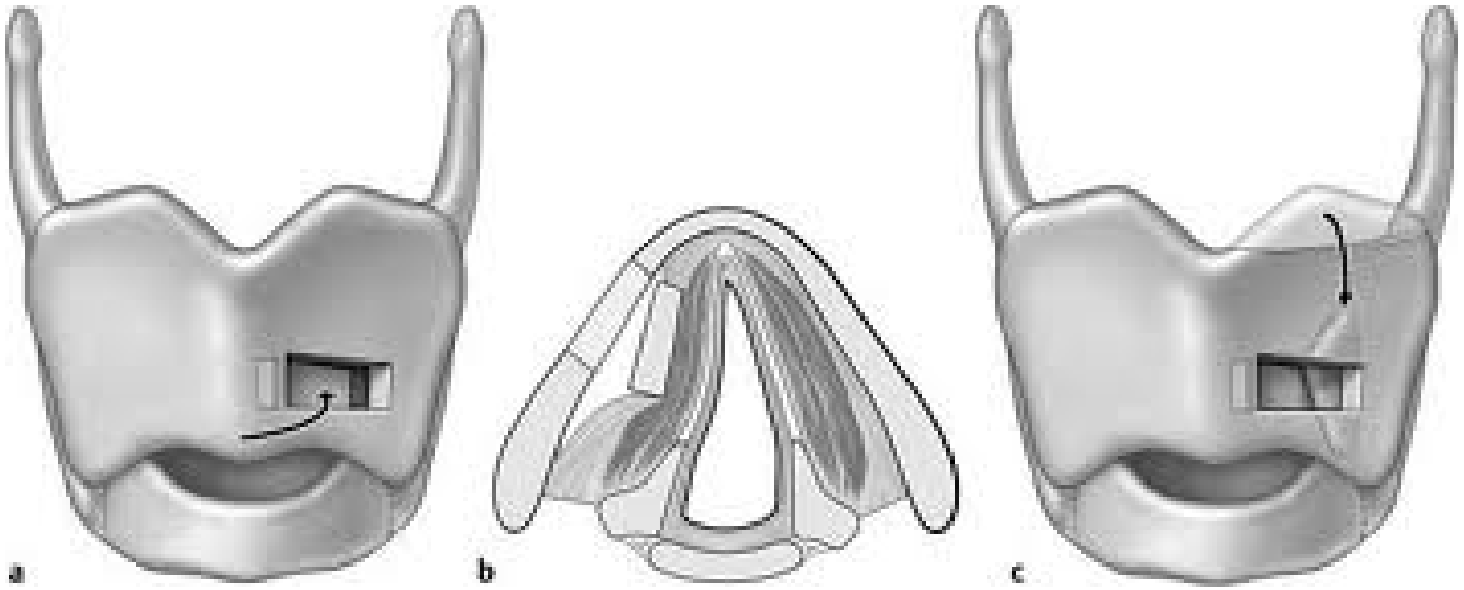

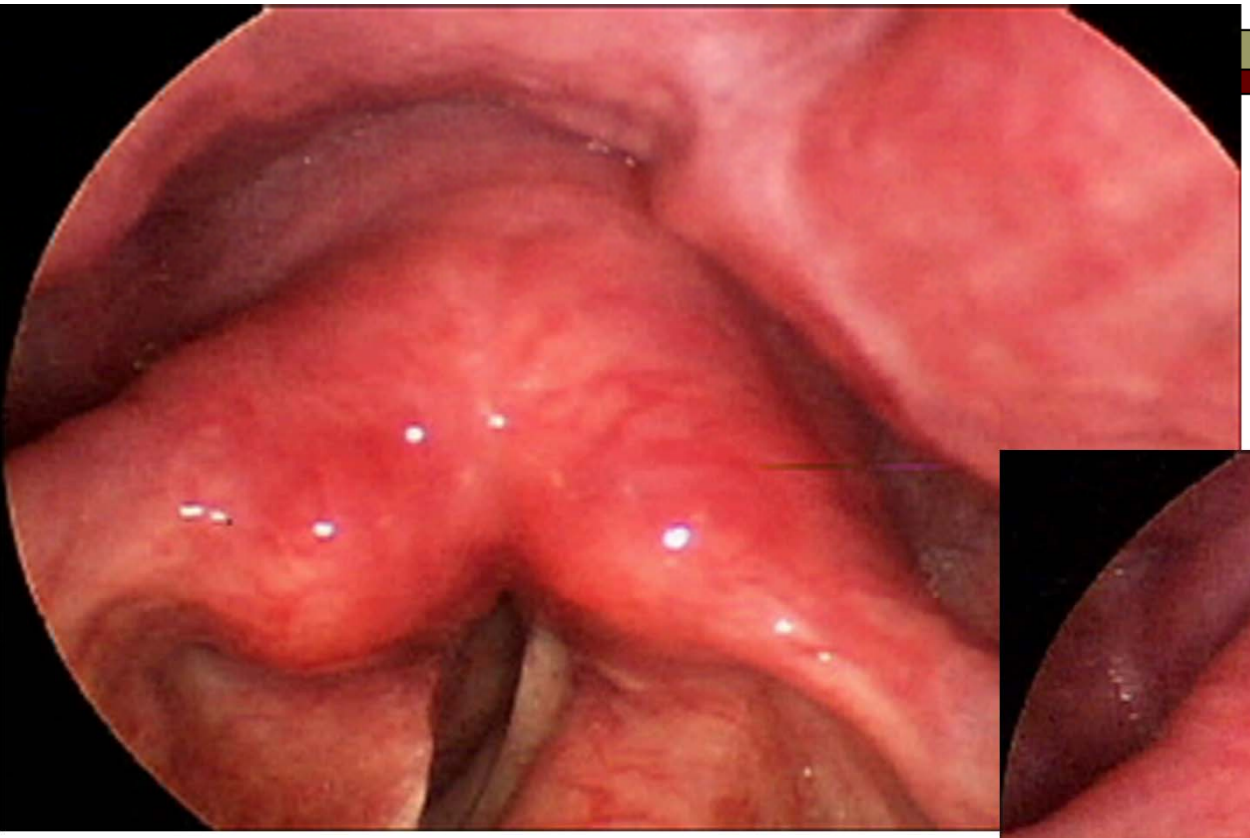

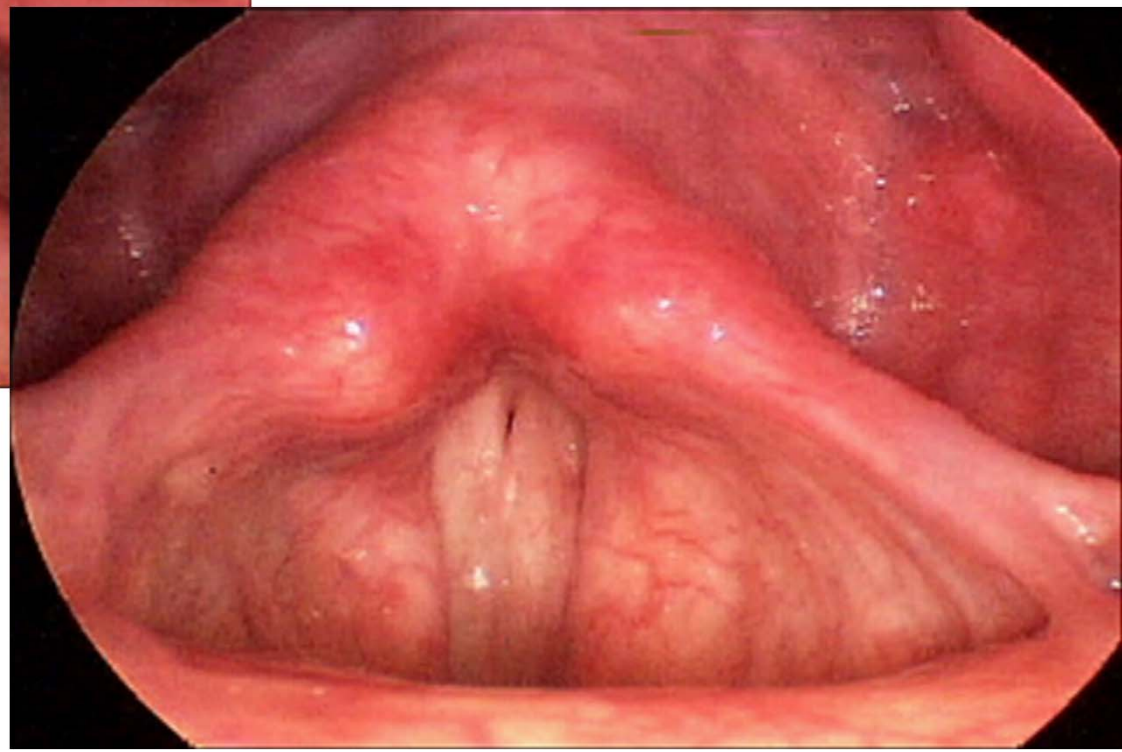

Neoplastic

Carcinoma

- Most commonly squamous cell carcinoma
- Anybody with hoarseness over a month should be evaluated
- Smoking and alcohol are risk factors
- Treat with surgery, radiation, occasionally chemo
- Speech path to aid with swallowing and sometimes speaking

Voice Disorders

- Functional
- Infectious
- Inflammatory
- Medication effects
- Traumatic
- Benign lesion
- Neurologic
- Neoplasms-malignant

Neoplastic

Carcinoma

Neoplastic

Carcinoma

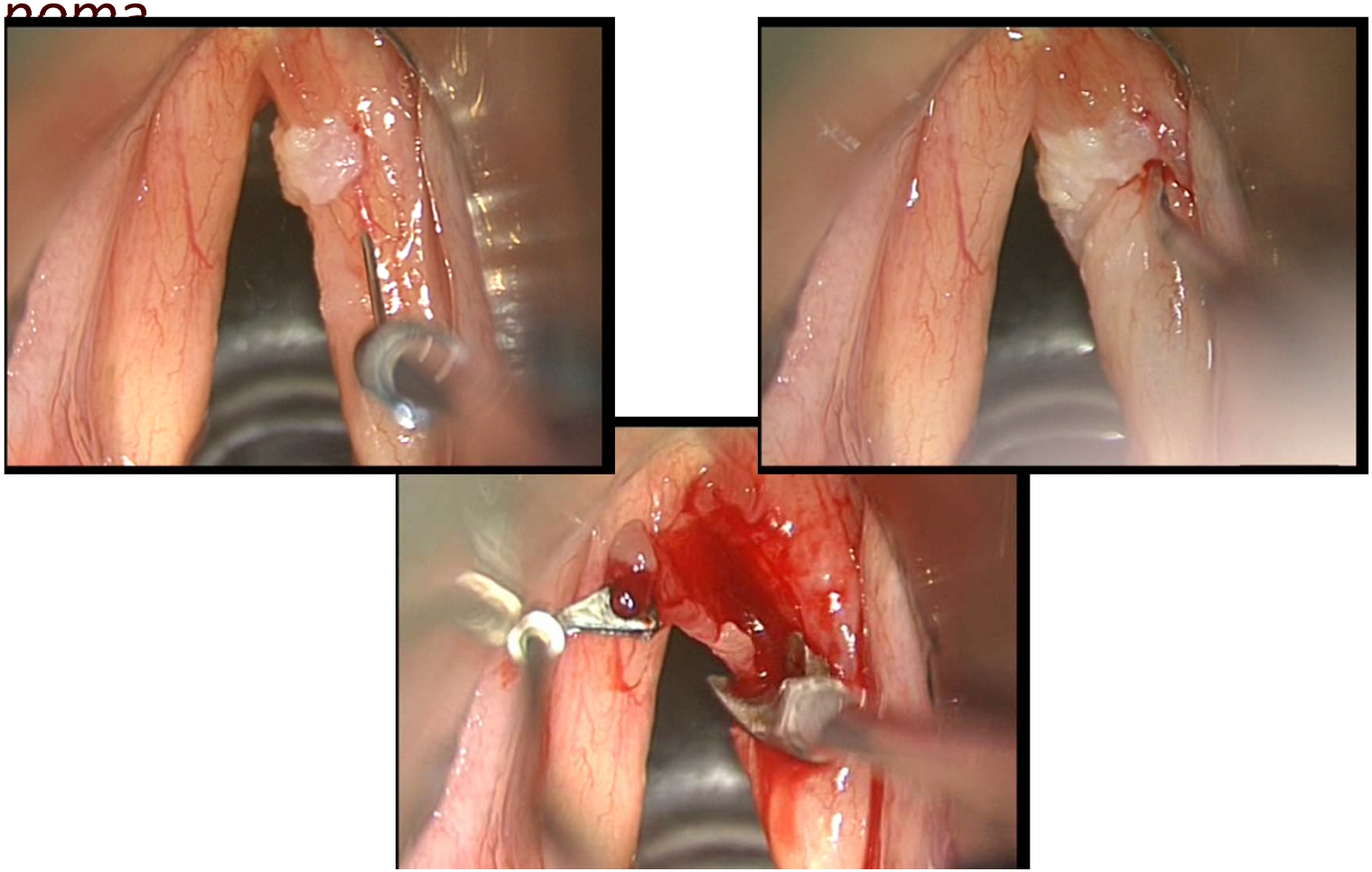

How To Assess A Patient

- HPI (or subjective) – who, what, how, when, where? How is it bothering them?



"Listen to your patient, he is telling you the diagnosis."

Post Lecture Quiz!

- 21 year old healthy female
- Worsening hoarseness over 1 year
- Takes no medications
- Very personable

Post lecture Quiz

- What is the diagnosis?
  - A. Normal voice for age
  - B. Vocal cord nodules
  - C. Improper technique/muscle tension
  - D. Vocal cord paralysis
  - E. Vocal cord polyp

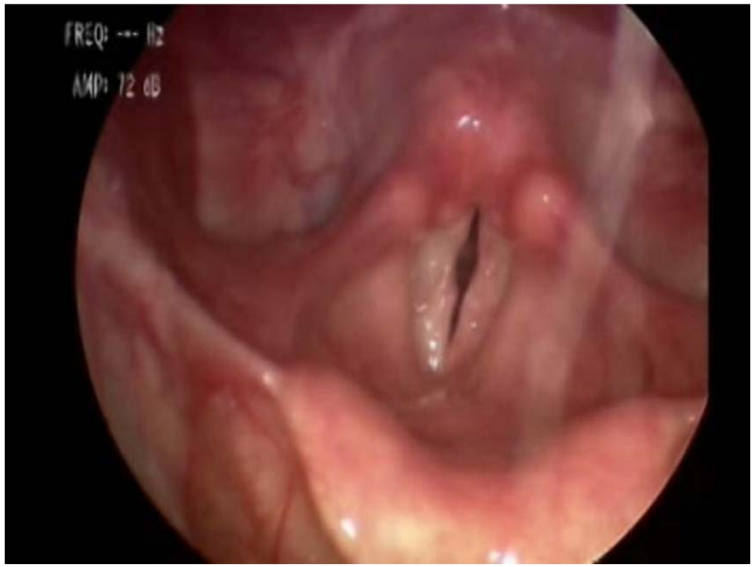

Nodules!

What Your Voice Says About You

- Can usually develop short list of differential diagnoses from history and by listening
- Individuals (particularly smokers) who are hoarse for over 1 month should have laryngeal exam

Voice Resources: Kansasvoicecenter.com
Voicefoundation.org
Voicedoctor.net