

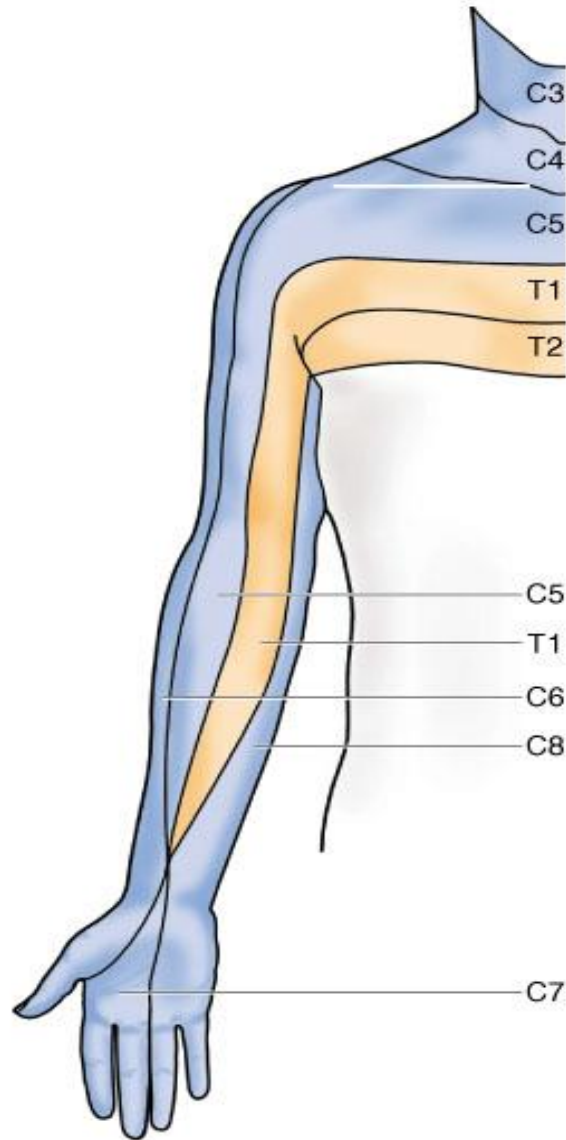
Dr. Donald Matz

Anatomy

Key Symptoms

- Pain, severe, and ongoing between shoulder blades and “dull ache” in mid-back and neck with numbness and tingling down the left forearm to the hand. Shooting pain down left arm wakes him up.
- No significant left-sided neuroforamina narrowing, mild cervical spondylosis otherwise unremarkable with MRI.
- Left hypothenar eminence atrophied
- Decreased pin prick over Medial epicondyle and stocking and glove pattern in the hands (C8).
- Triceps Reflex diminished on left, C7
- No finding of Spasticity or Flaccidity
- Weakness in intrinsic muscles of the hand

Dermatomes

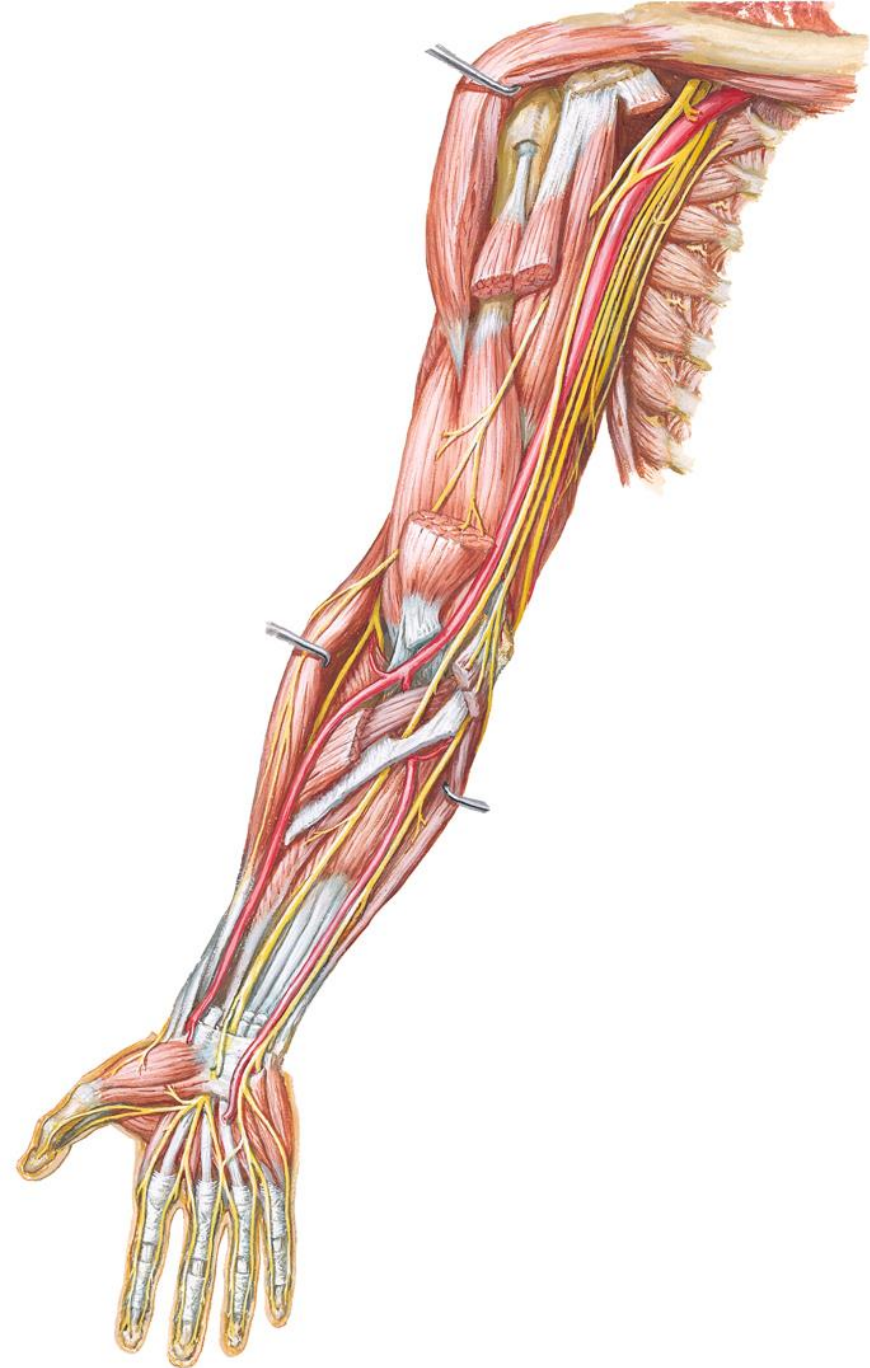


Segmental innervation of skin (dermatomes)

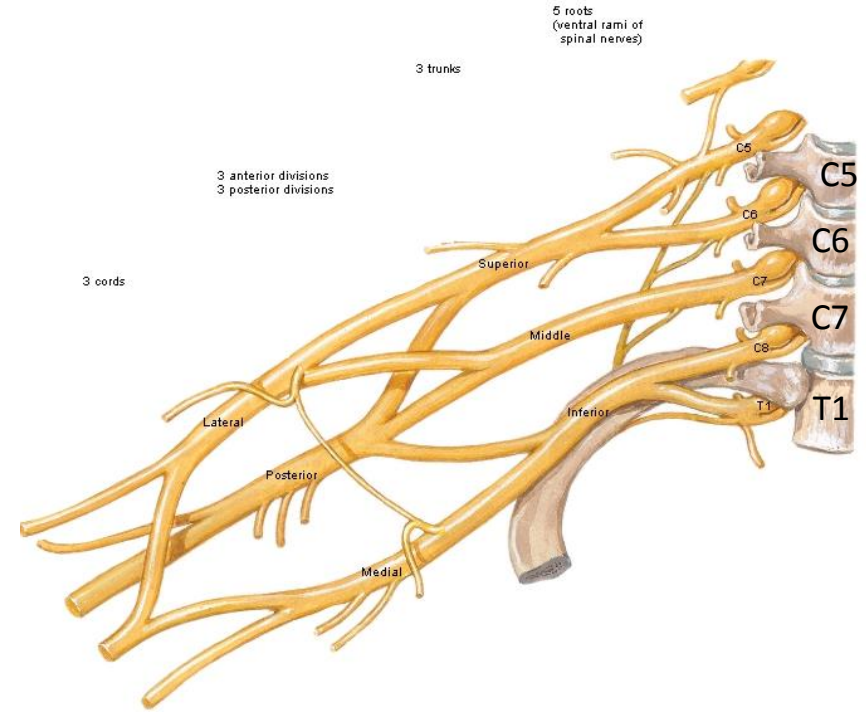
(A) Anterior views

Important Spinal Cord Myotome levels

- C5—Deltoid, Biceps Brachii Tendon Reflex
- C6—Wrist Extensors, Brachioradialis Tendon Reflex
- C7—Wrist Flexors (primarily Flexor Carpi Radialis), Finger extensors, Triceps Brachii Tendon Reflex
- C8—Finger flexors
- T1—Finger Abduction and Adduction



Brachial Plexus: Schema

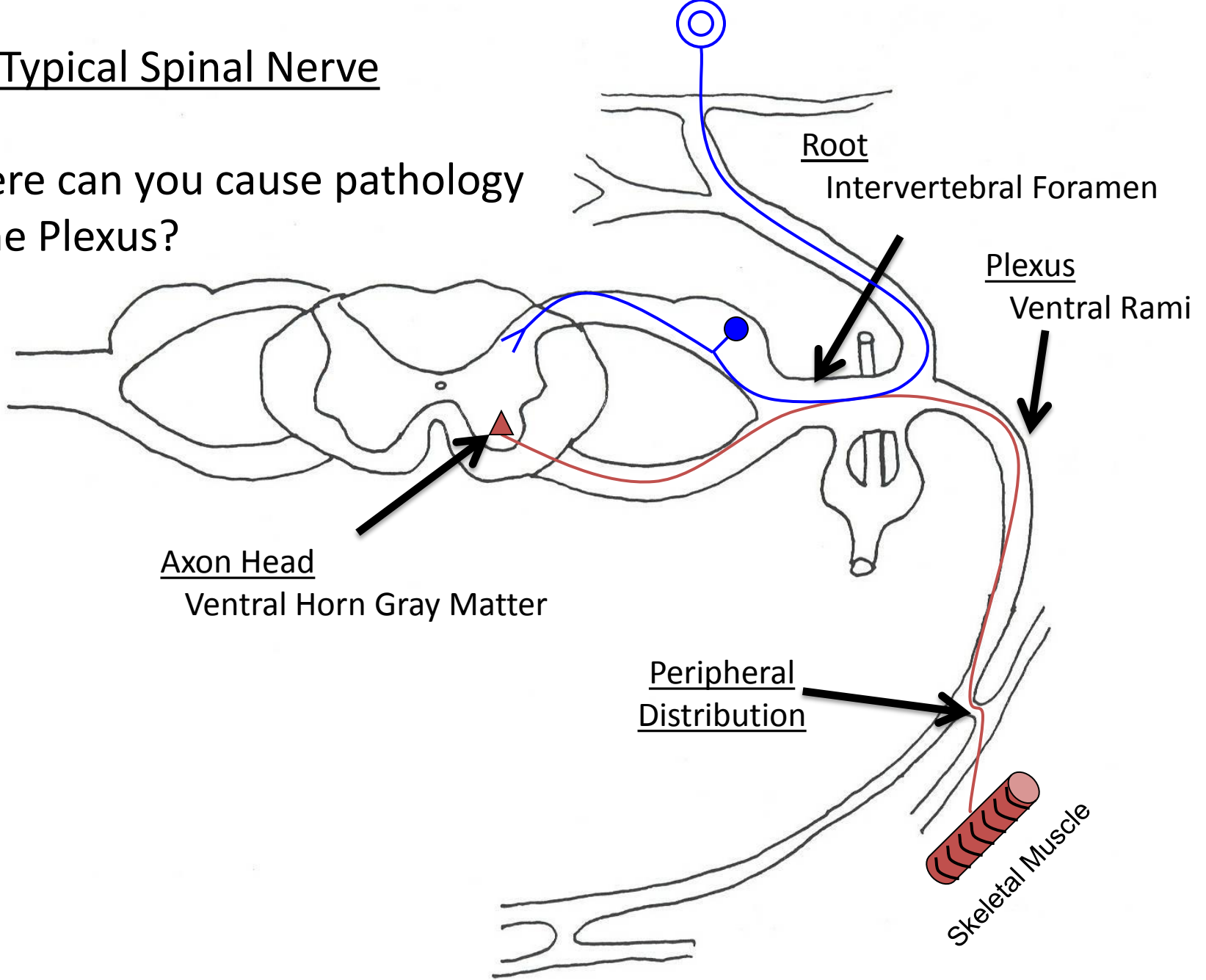


F. Netter
M.D.
© IBV

F. Netter
M.D.

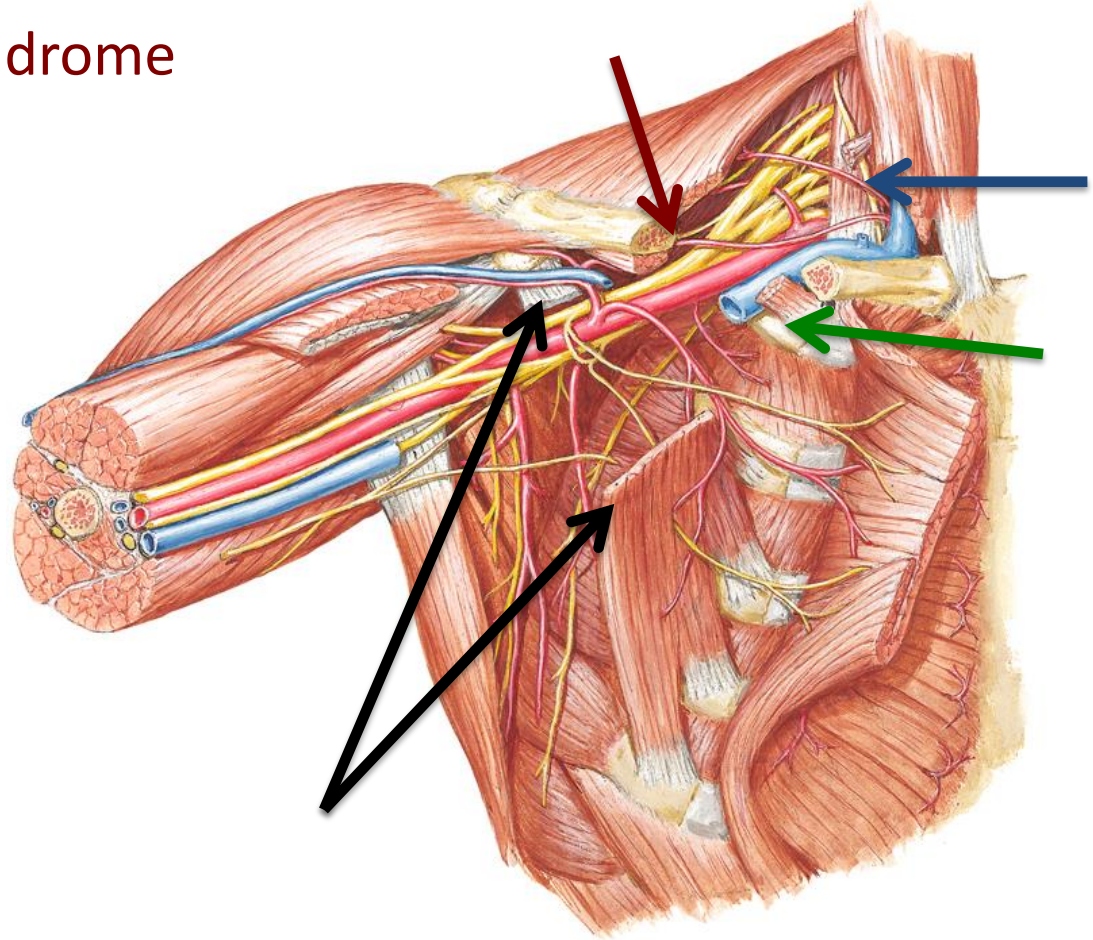
The Typical Spinal Nerve

Where can you cause pathology in the Plexus?



Brachial plexus Injuries-Thoracic Outlet Syndrome

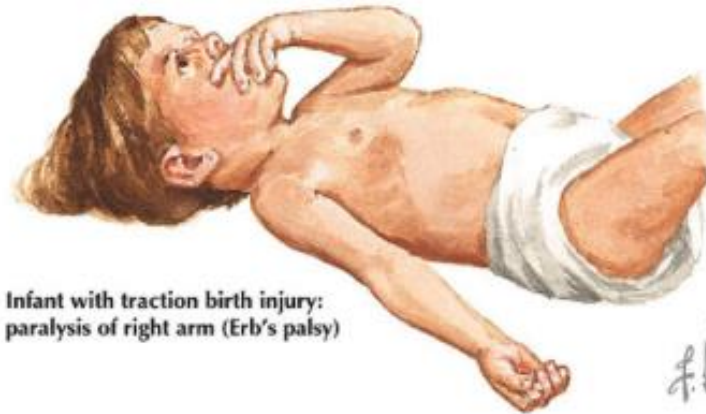
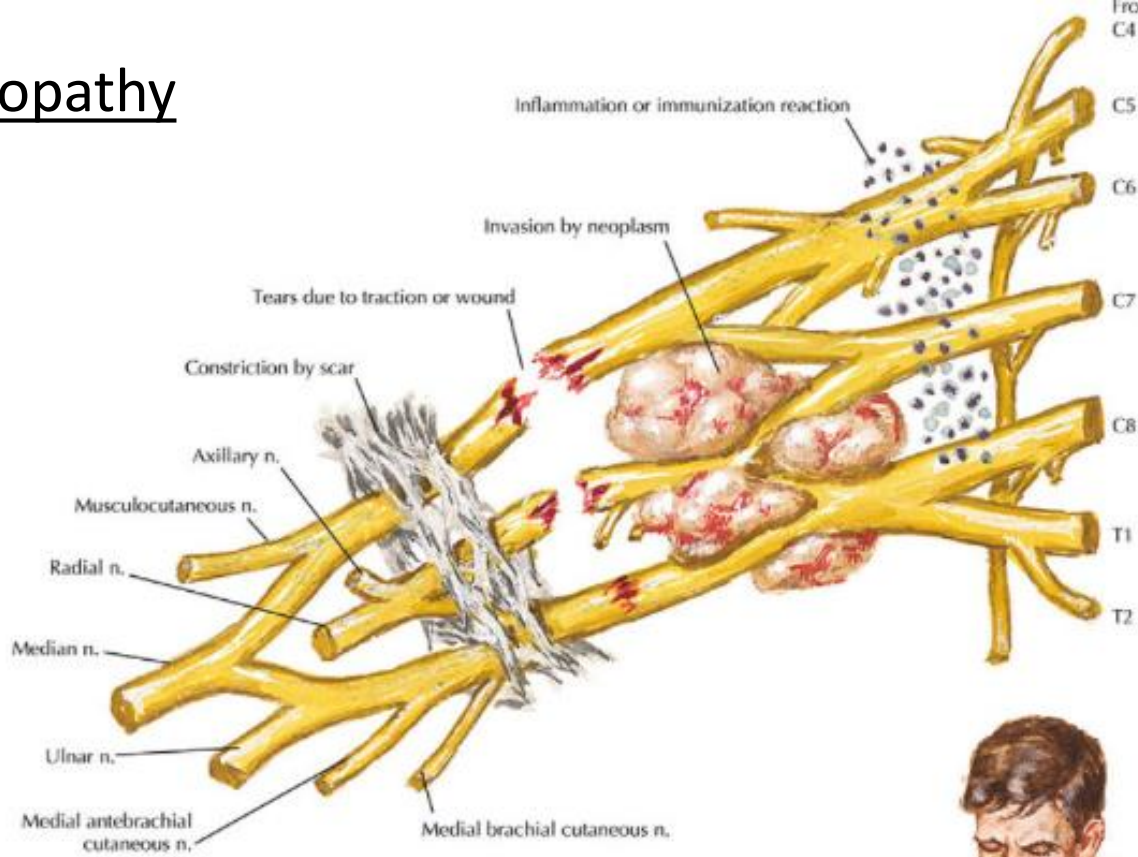
1. **Scalenes**
2. **Cervical Ribs**
3. **Costoclavicular Syndrome**
4. **Pectoralis Minor**



*F. Netter
M.D.*

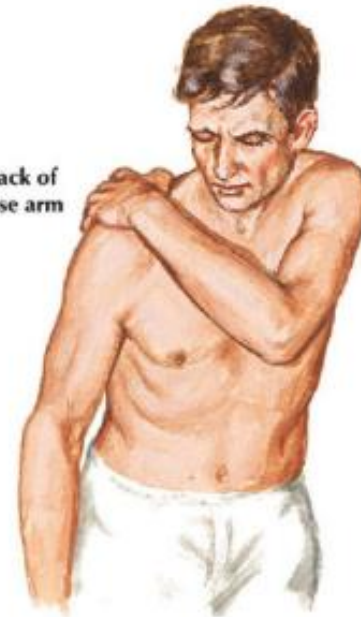
Brachial Plexopathy

Causes??



**Infant with traction birth injury:
paralysis of right arm (Erb's palsy)**

**Acute onset of pain in back of
shoulder: inability to raise arm**



F. Netter M.D.