FASST

Foot & Ankle Symposium & Surgical Techniques

Brought to you in partnership by

BESPA GLOBAL

DES MOINES UNIVERSITY
MEDICINE & HEALTH SCIENCES

STJ Calcaneal Distraction Arthrodesis

Sean T. Grambart DPM FACFAS
Assistant Professor and Assistant Dean of Academic Affairs, Des Moines University, College of Podiatric Medicine and Surgery
Past-President, American College of Foot and Ankle Surgeons

Disclosure

- Partner, BESPA Global
- Orthosolutions, Design Team Member
- ACFAS, Speaker

Calcaneal Fracture Mechanics

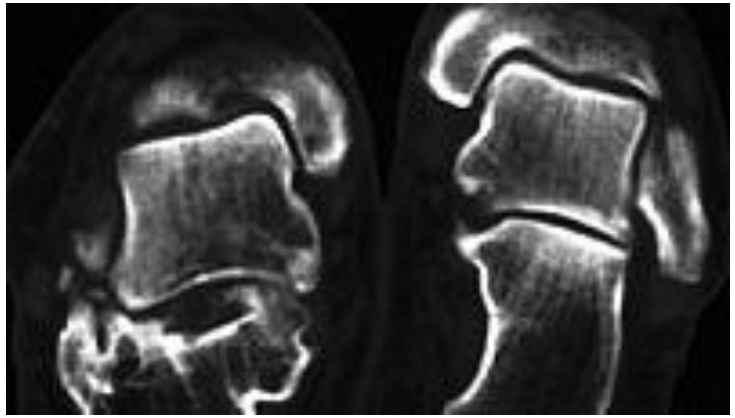

- Painful STJ arthritis
- Anterior ankle impingement
- Decreased calcaneal height
- Longitudinal arch collapse
- Fibulocalcaneal abutment
- Peroneal impingement
- Axial hindfoot malalignment
- Decreased achilles tendon lever arm

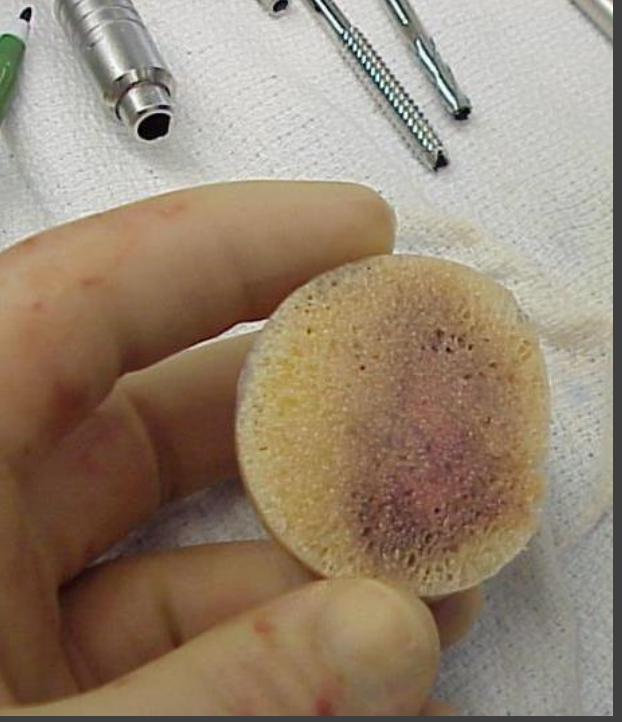

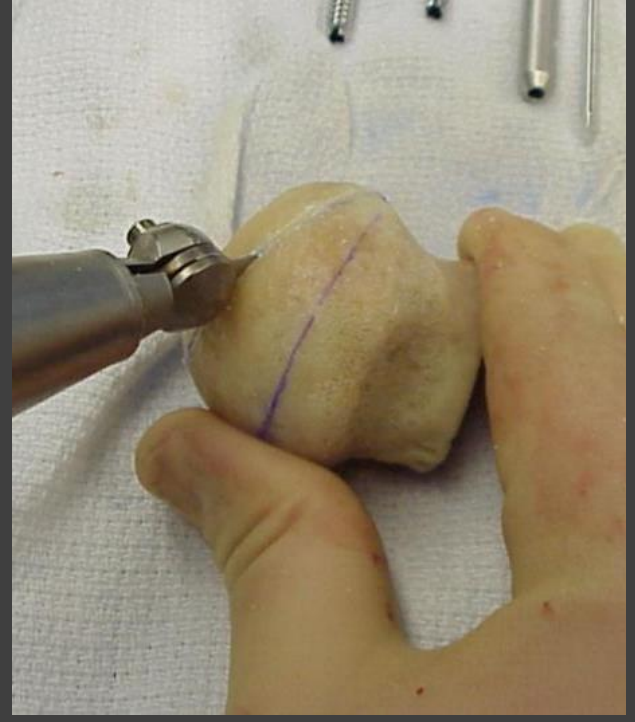

Distraction Arthrodesis

- Autogenous *vs* allograft
  - Frozen femoral head
  - Frozen Iliac Crest
- Wedge
  - Posteriorly placed
  - Larger medially
    - Correct for *some* varus

Distraction Arthrodesis

- Cancellous Grafting
  - Augmentation intergraft space

Allograft vs. Autograft

- 15 Patients with allograft
  - Mean Age 47.5
  - Mean Follow up 20.6 months
- 14 Complete Unions 1 nonunion
- Allograft results in similar union rates as autogenous grafting

J Foot Ankle Surg. 2010 Jul-Aug;49(4):369-74. Epub 2010 May 11.

Distraction arthrodesis of the subtalar joint using allogeneic bone graft: a review of 15 cases.

Lee MS, Tallerico V.

Dialing in Correction

- Distract joint until radiographic angles are restored

Fixation

- Fully threaded screws
- Should cross both sides of the host-graft interface

Radiographs

- *After fixation*
- 2 most important rearfoot alignment parameters
- (Rammelt et al)
  - Talocalcaneal height
  - Talar 1st Matatarsal angle

WEIGHT BEARING
R
MRT

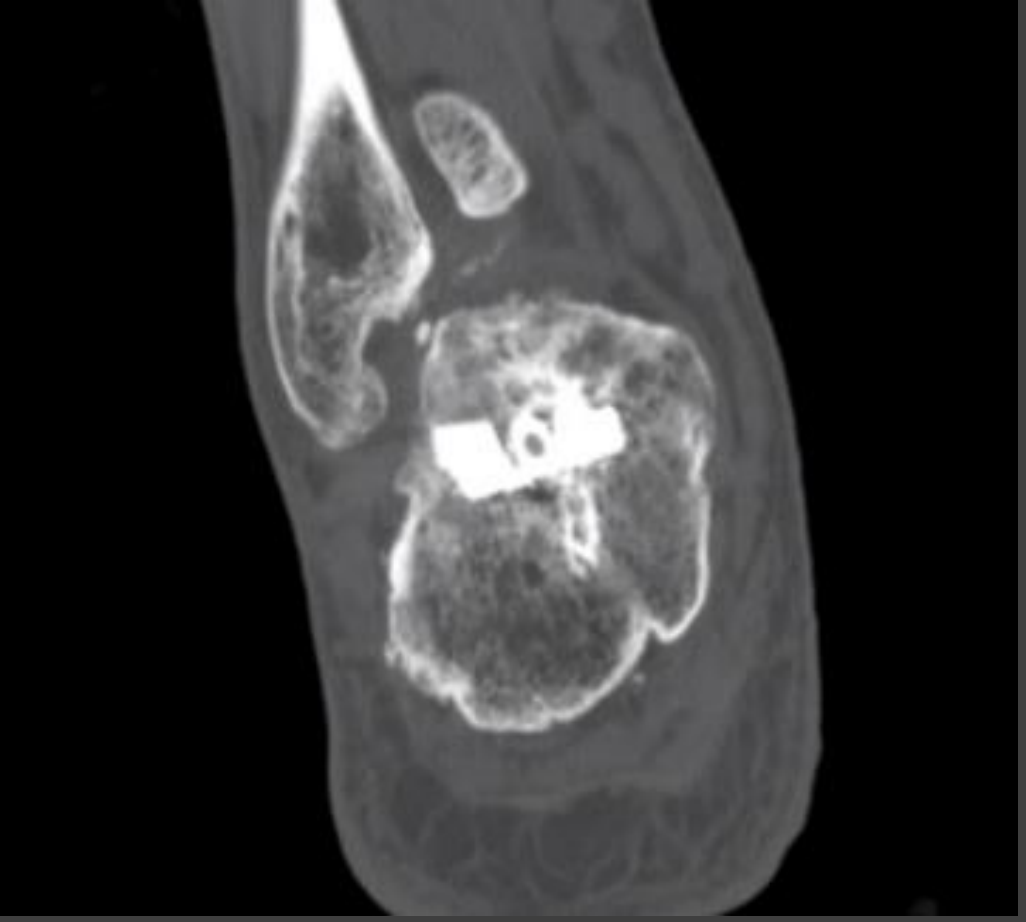

6 years PO

Post Operative Course

- Posterior Splint until Incision heals
- Fracture Boot NWB 8-10 weeks
- Ankle Early Range of motion begins after incisional healing
- Progressive Weight bearing to tolerance
- Functional Rehab as indicated
- Bone Stimulation?

Keys to Success

- Prone position easier exposure
- Aggressive Lateral Wall Decompression
- Lamina Spreader as far medial as possible
- Truncated Wedge Larger medial
- Thou Shall Not Compress
- Orthobiolgics



FASST
FOOT & ANKLE SYMPOSIUM & SURGICAL TECHNIQUES
NEW COURSE:
DIABETIC DILEMMA'S
FEBRUARY 12-14, 2021
BROUGHT TO YOU IN PARTNERSHIP BY
DES MOINES UNIVERSITY
MEDICINE & HEALTH SCIENCES
BESPA
GLOBAL

Thank You!