DMU Clinic Grand Rounds

60 year old male with ACL injury

Laura Covill, D.P.T., OCS, COMT
Donald Matz, Ph.D.
Yogesh Shah, M.D.

Objectives

- Correlate patient history and physical findings to the care plan, examination, and subsequent actions.
- Present and exchange ideas from a multidisciplinary approach to patients, diagnoses, treatment and overall plan of care.
- Project common understanding among a broad range of specialties which enhance a positive group culture.

The history and initial PT examination

- 60 year old male with 10 year history of L knee problems referred to P.T. with dx of ACL tear, medial meniscus tear.
- Patient relates new knee injury 2 months ago when golfing and assisting his son when moving furniture. Notices increased buckling of the knee.
- PMH – hypertension and high cholesterol
- Lower extremity functional scale (LEFS) at 49/100
- L knee swollen, lacking 5 degrees of extension
- Quad atrophy with 4/5 strength in both hips and knees bilaterally.
- + Lachman's, difficulty squatting, +McMurray, lateral joint line pain
- Patient goals- decrease buckling of knee, avoid surgery

Treatment for ACL

- Patient progressed through PT without problems and after 2 months of treatment was showing full range of motion, improvement in knee buckling. LEFS 70/80. Patient to return for one more visit in 2 weeks before d/c
- Patient returned to PT complaining of occasional symptoms of R hand, L foot and R flank tingling
- The physical therapist reassessed and noted spotty loss of sensation of light touch on medial forearm, and ring and small finger and spotty sensation on dorsum and plantar surface of L foot.
- Patient was referred to his primary care physician with phone call and written documentation. Patient was discharged from PT since patient has met PT goals and was independent in a HEP of strengthening. Patient was instructed to visit with his primary care physician

Primary Care – 3 days later

- Patient complaint – “numbness in hands and feet that comes and goes”
- Examination of sensation was normal, strength was normal
- CBC – normal
- Placed on gabapentin, referred to neurology brain CT
- Brain CT -normal

Neuro consult- 1 month later

- Patient c/o – numbness in hands, feet, trunk, problems walking
- Neuro exam – normal for sensation, motor, cranial n., bowel/bladder, mentation, speech, 2+ reflexes in UE and LE

Neuro consult (con.)

- Differential DX: progressive paresthesias with gait disorder, sensory ataxia without objective sensory loss
- Etiology - ?toxic sensory neuropathy, ? Cervical myelopathy, ?paraneoplastic syndrome (but no carcinoma)
- Tests –Immunofixation serum, CBC, electrolytes, MRI and EMG

ER Visit

- Patient’s condition suddenly deteriorated with loss of strength in his LE with gait abnormalities and he went to the ER.

MRI scans of a patient with cervical spondylosis.

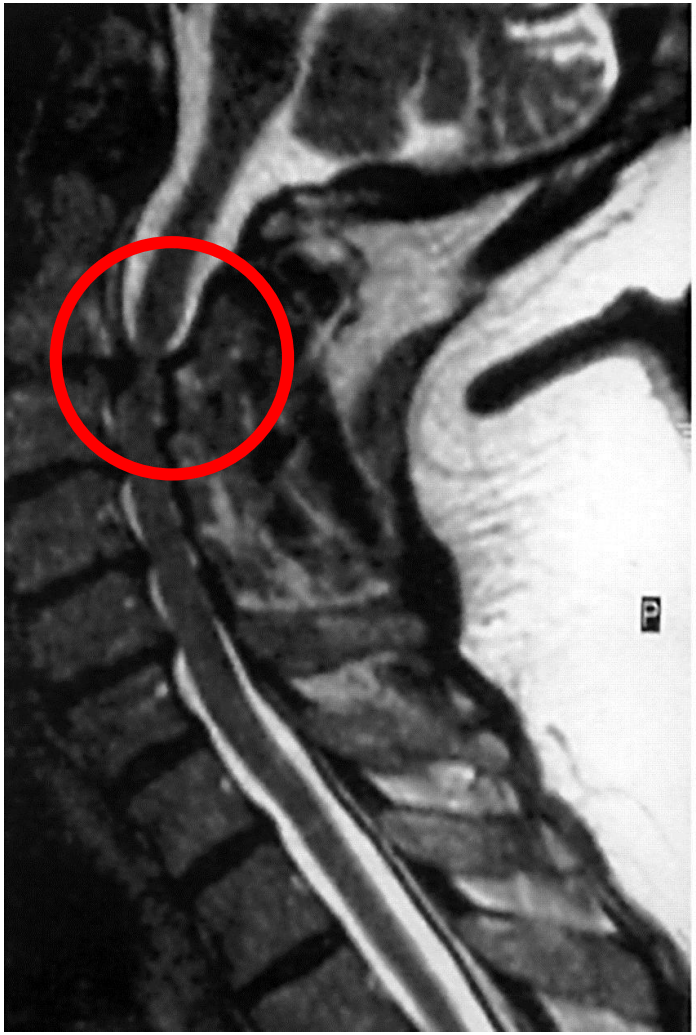

Malcolm G P J Neurol Neurosurg Psychiatry 2002;73:i34-i41

JNNP

MRI scans of a patient with cervical spondylosis.

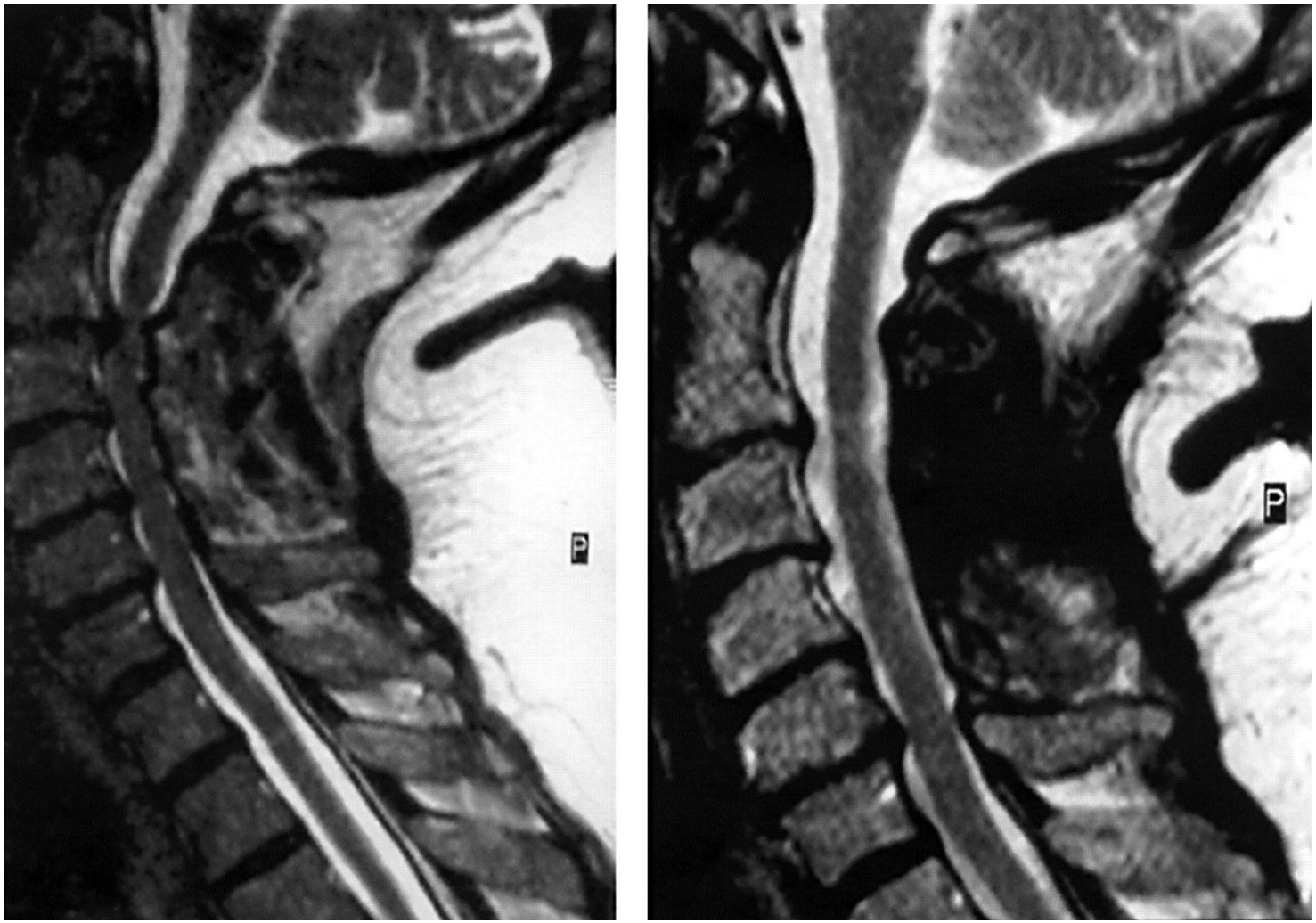

Malcolm G P J Neurol Neurosurg Psychiatry 2002;73:i34-i41

cord compression

- He was admitted and subsequently had a cervical laminectomy for central cord compression.
- 2 months later patient complained to neurosurgeon about his gait and weakness – referred to physical therapy

Physical therapy 2 months later

Chief complaint – weakness in legs L>R, poor gait, unable to do prior level of recreation (golf and elliptical machine)

Slightly better since surgery

Examination –

- ↓ sensation to light touch in medial forearm, R thumb and index finger, dorsum and plantar aspect of the L foot
- L hip and knee musculature 3/5, Grip strength diminished on R hand,
- Gait with ↓ push-off, ↓DF, ↓ knee flexion, ↑circumduction
- LEFS – 32/80

Cervical Laminectomy

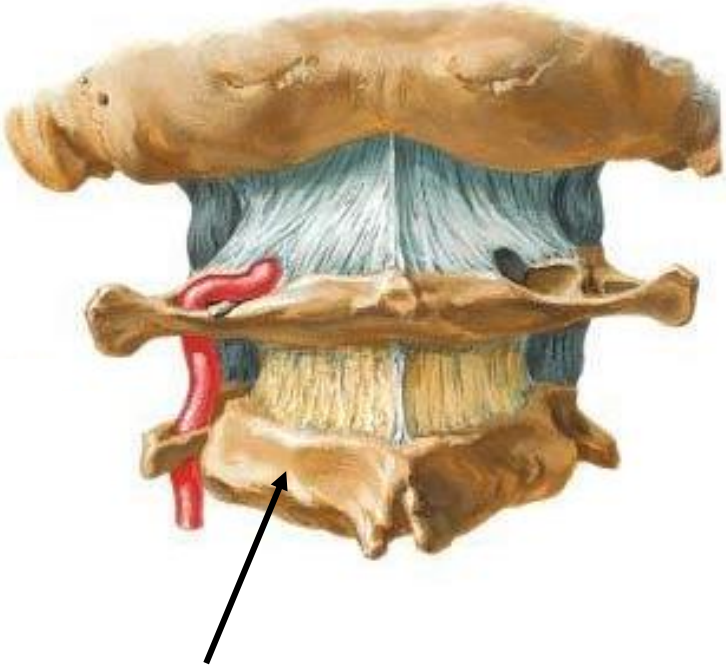

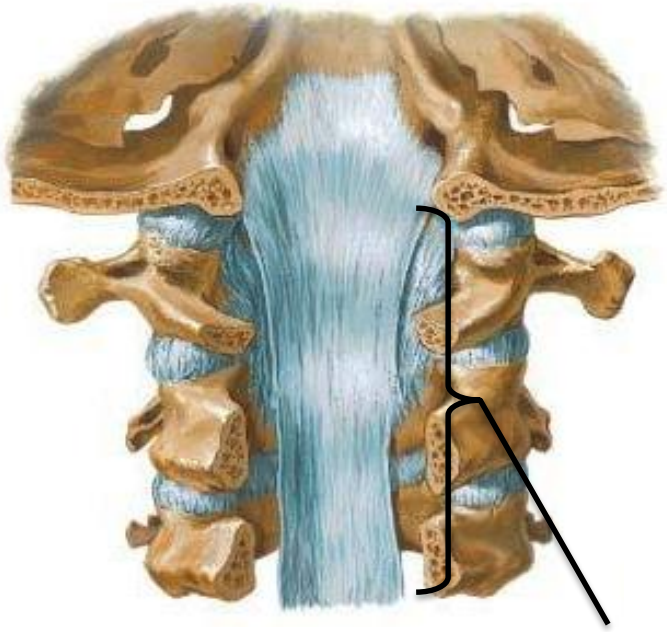

Gait Ataxia-Neuroanatomy

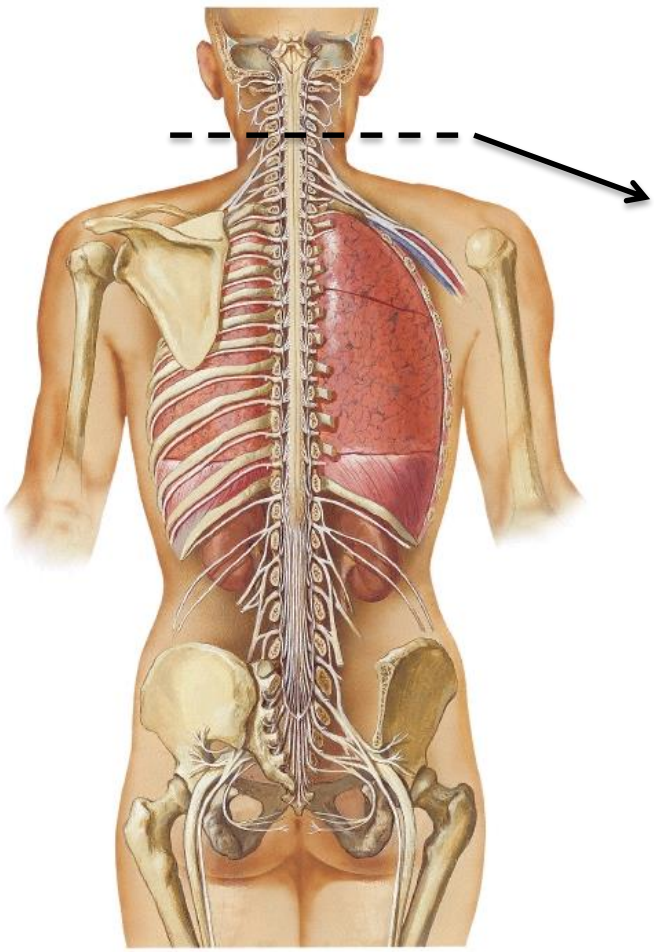

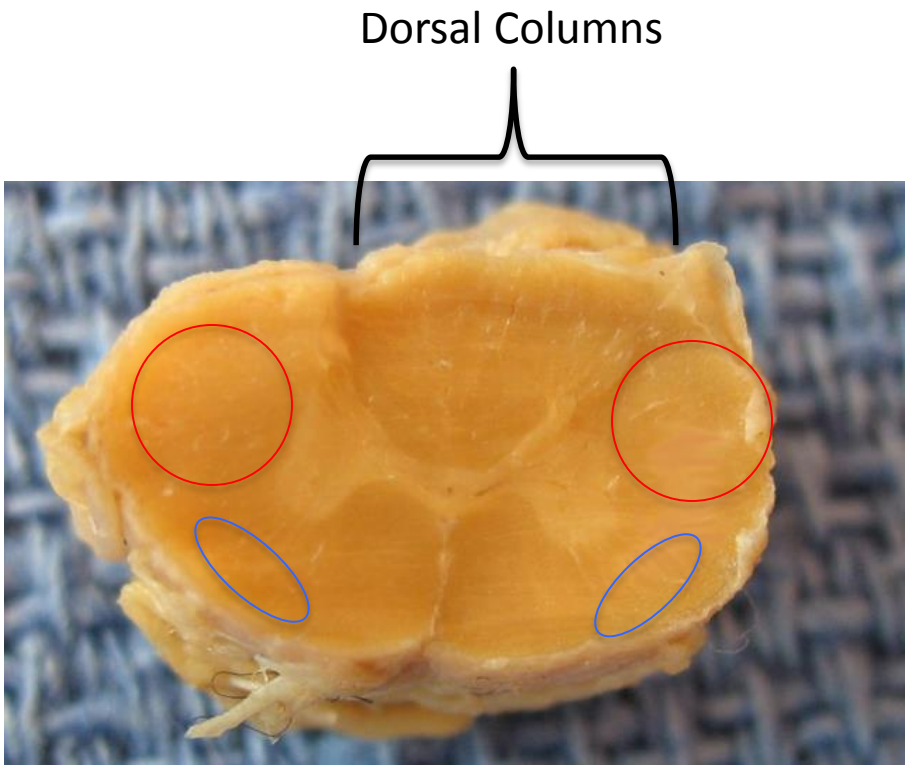

Corticospinal Tract (Upper Motor Neuron)

Anterolateral System (Spinothalamic Tract)

F. Netter M.D. ©IGN

Sensory and Motor Symptoms

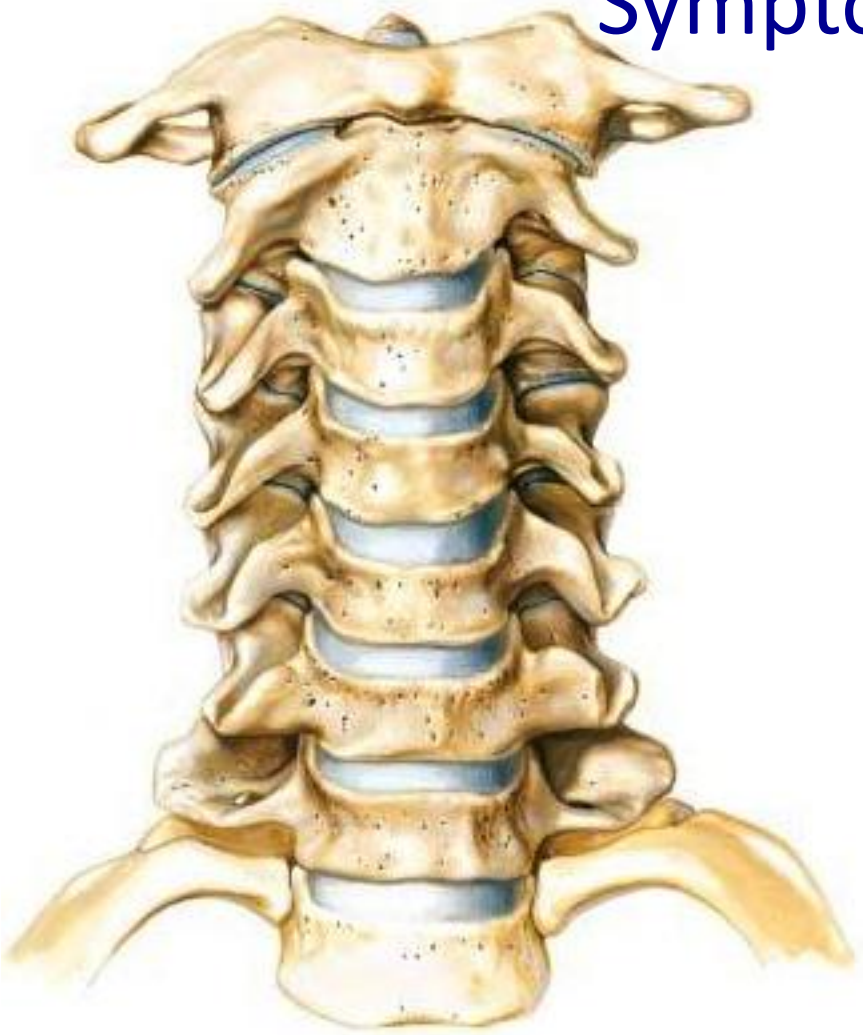

6.11A, left. Segmental innervation of skin (dermatomes), anterior.

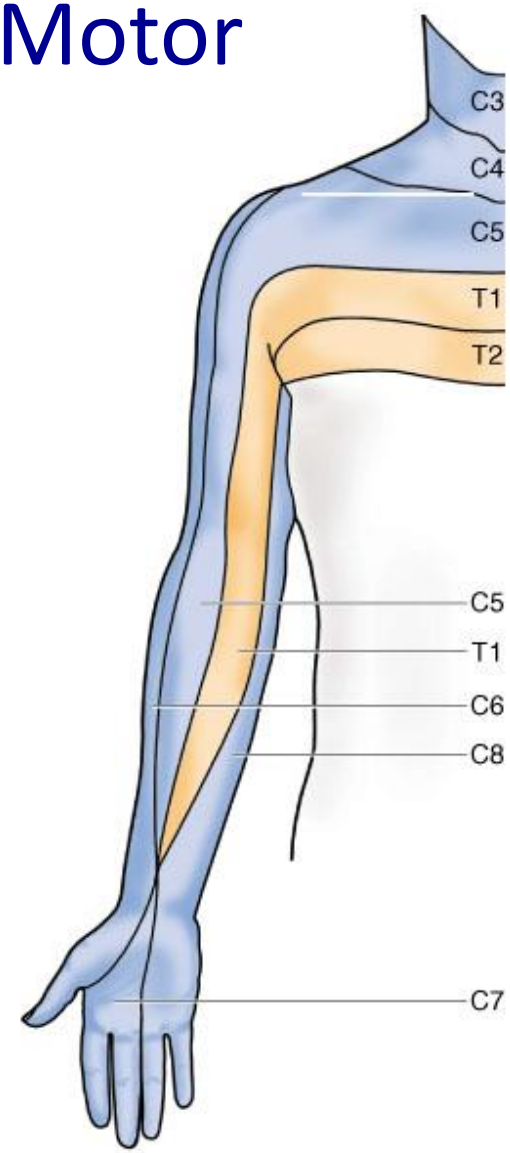

Segmental innervation of skin (dermatomes)

(A) Anterior views

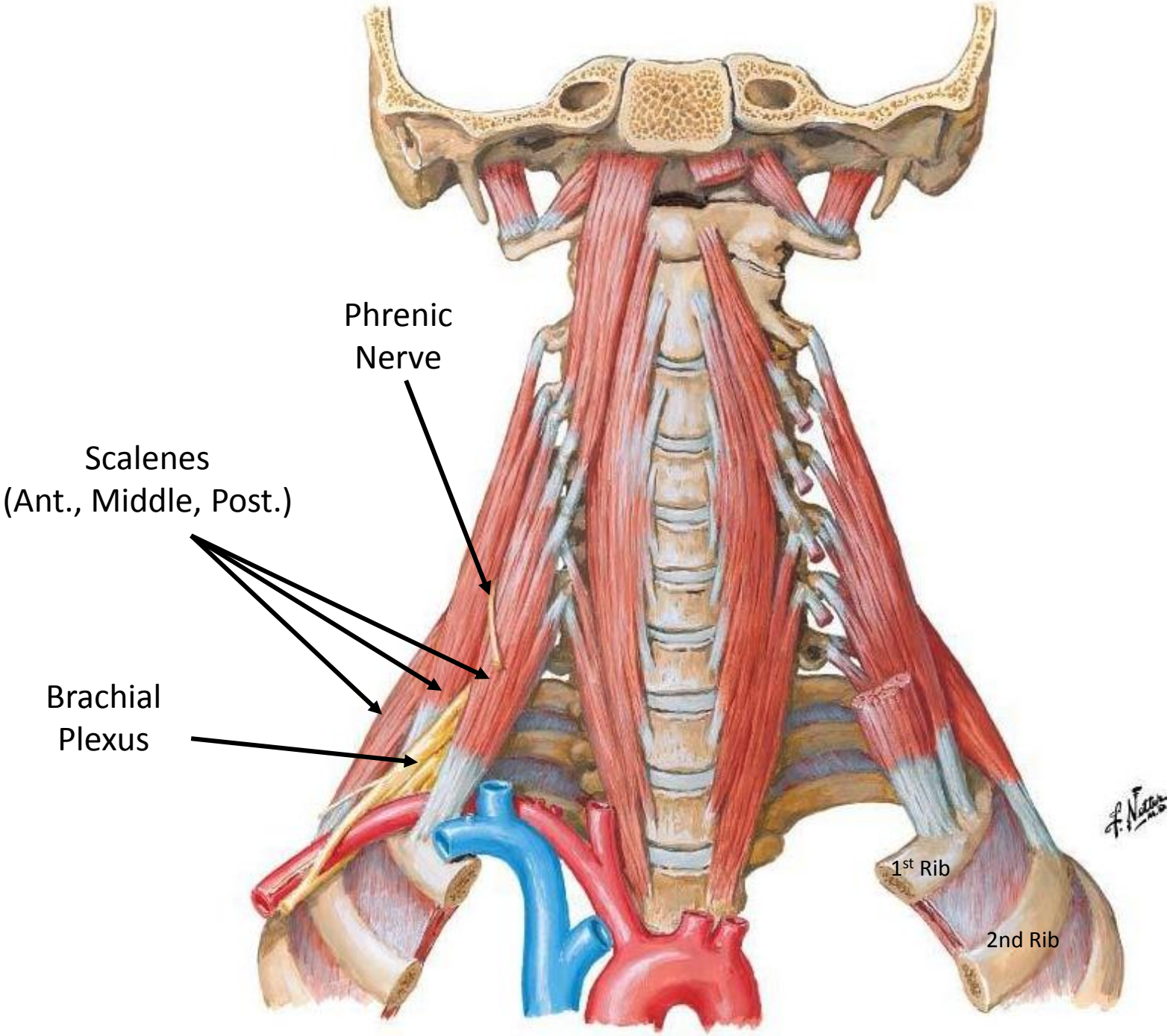
Phrenic
Nerve
Scalenes
(Ant., Middle, Post.)
Brachial
Plexus
1st Rib
2nd Rib

Brachial Plexus: Schema

5 Roots
(Ventral Primary Rami of C5-T1)

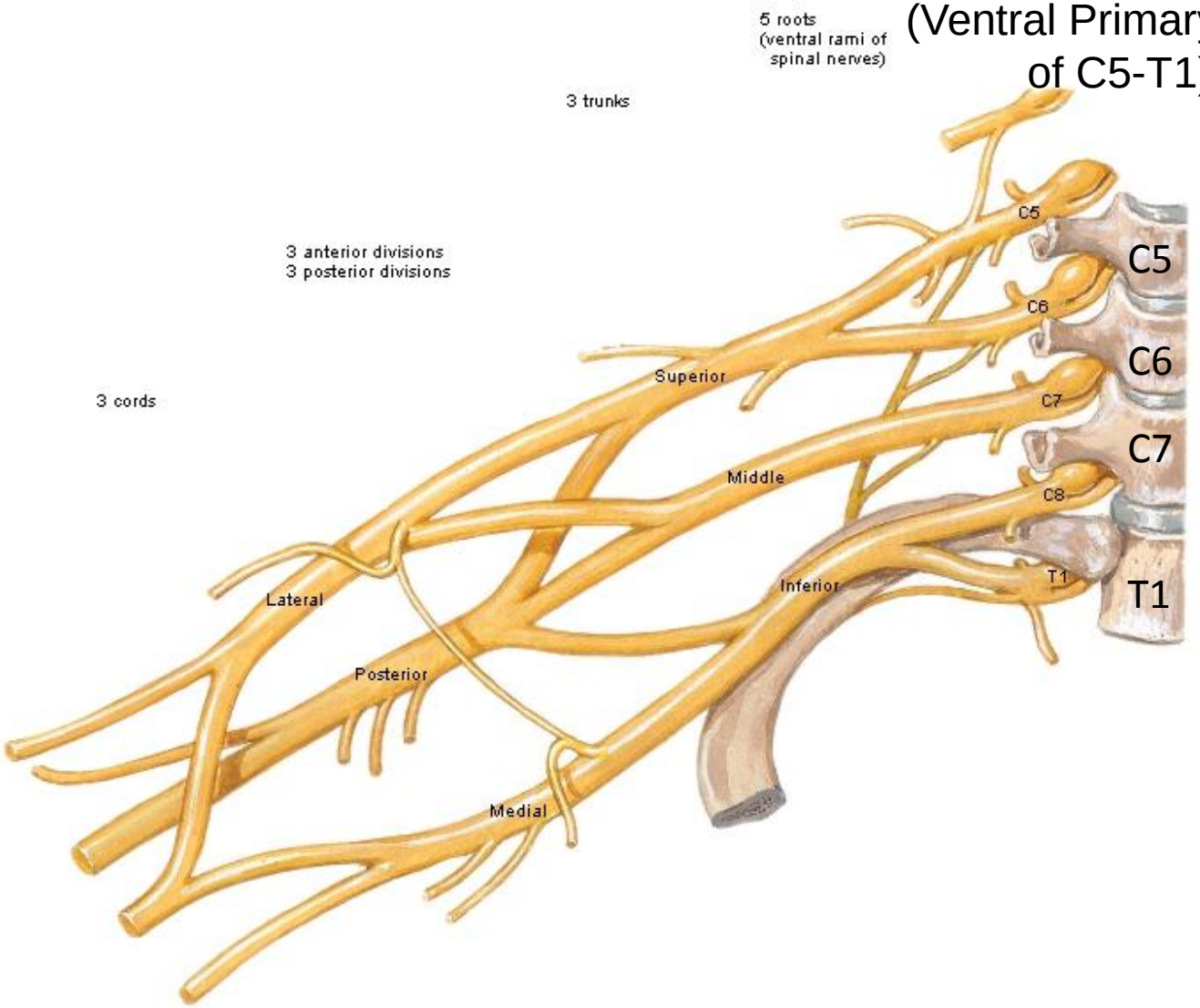

F. Netter M.D.
©IGN

Physical therapy treatment for 2 months

- Strength in L lower extremity now 4/5
- Paresthesias improved but not gone
- Returned to golfing
- Work outs consist of 20 minutes elliptical/20 minutes strengthening 2-3 times per week
- Gait almost normal when walking slowly; with increase in speed or fatigue, gait deteriorates with hip circumduction and decreased knee flexion
- LEFS 62/80
- Patient and therapist decide patient can continue strengthening at home with home program

Questions

- Next Grand Round- Nov. 7th 7 AM